

Chinese expert consensus on sequential surgery following conversion therapy based on combination of immune checkpoint inhibitors and antiangiogenic targeted drugs for advanced hepatocellular carcinoma (2024 edition)

Haowen Tang^{1,§}, Wenwen Zhang^{1,§}, Junning Cao^{2,§}, Yinbiao Cao^{1,§}, Xinyu Bi^{3,§}, Haitao Zhao^{4,§}, Ze Zhang¹, Zhe Liu¹, Tao Wan⁵, Ren Lang⁶, Wenbing Sun⁶, Shunda Du⁴, Yongping Yang⁷, Yinying Lu⁸, Daobing Zeng⁹, Jushan Wu⁹, Binwei Duan⁹, Dongdong Lin¹⁰, Fei Li¹⁰, Qinghua Meng¹¹, Jun Zhou¹², Baocai Xing¹³, Xiaodong Tian¹⁴, Jiye Zhu¹⁵, Jie Gao¹⁵, Chunyi Hao¹⁶, Zhiqiang Wang¹⁷, Feng Duan¹⁸, Zhijun Wang¹⁸, Maoqiang Wang¹⁸, Bin Liang¹, Yongwei Chen¹, Yinzhe Xu¹, Kai Li¹, Chengang Li¹, Minggen Hu¹, Zhaohai Wang¹, Shouwang Cai¹, Wenbin Ji¹, Nianxin Xia¹⁹, Wenheng Zheng²⁰, Hongguang Wang³, Gong Li²¹, Ziman Zhu²², Zhiyong Huang²³, Wanguang Zhang²³, Kaishan Tao²⁴, Jun Liang²⁵, Keming Zhang²⁶, Chaoliu Dai²⁷, Jiangtao Li²⁸, Qiu Qiu²⁹, Yuan Guo², Liqun Wu², Weibao Ding³⁰, Zhenyu Zhu³¹, Wanqing Gu³², Jingyu Cao³³, Zusen Wang³³, Lantian Tian³³, Huiguo Ding³⁴, Guangming Li³⁵, Yongyi Zeng³⁶, Kui Wang³⁷, Ning Yang³⁷, Haosheng Jin³⁸, Yajin Chen³⁹, Yinmo Yang⁴⁰, Dianrong Xiu⁴¹, Maolin Yan⁴², Xiaodong Wang⁴³, Quanli Han⁴⁴, Shunchang Jiao⁴⁴, Guang Tan⁴⁵, Jizhou Wang⁴⁶, Lianxin Liu⁴⁶, Jinghai Song⁴⁷, Jiajie Liao⁴⁸, Hong Zhao³, Peng Li⁴⁹, Tianqiang Song⁵⁰, Zhanbo Wang⁵¹, Jing Yuan⁵¹, Bingyang Hu⁵², Yufeng Yuan⁵³, Meng Zhang⁵⁴, Shuyang Sun⁵⁵, Jialin Zhang⁵⁶, Wentao Wang⁵⁷, Tianfu Wen⁵⁷, Jiayin Yang⁵⁷, Xilin Du⁵⁸, Tao Peng⁵⁹, Feng Xia⁶⁰, Zuojin Liu⁶¹, Weibo Niu⁶², Ping Liang⁶³, Jianming Xu⁶⁴, Xiao Zhao⁶⁵, Min Zhu⁶⁶, Huaizhi Wang⁶⁷, Ming Kuang⁶⁸, Shunli Shen⁶⁸, Xing Cui⁶⁹, Jinxue Zhou⁷⁰, Rong Liu¹, Huichuan Sun⁷¹, Jia Fan⁷¹, Xiaoping Chen²³, Jian Zhou⁷¹, Jianqiang Cai³, Shichun Lu^{1,*}; Professional Committee for Prevention and Control of Hepatobiliary and Pancreatic Diseases of Chinese Preventive Medicine Association, Chinese Society of Liver Cancer, Liver Study Group of Surgery Committee of Beijing Medical Association, Editorial Board of the Chinese Journal of Hepatobiliary Surgery.

¹ Faculty of Hepato-Pancreato-Biliary Surgery, the First Medical Center of the Chinese PLA General Hospital, Institute of Hepatobiliary Surgery of the Chinese PLA, Beijing, China;

² Organ Transplantation Center, the Affiliated Hospital of Qingdao University, Shandong, China.;

³ Department of Hepatobiliary Surgery, National Cancer Center/National Clinical Research Center for Cancer/Cancer Hospital, Chinese Academy of Medical Sciences and Peking Union Medical College, Beijing, China;

⁴ Department of Liver Surgery, Peking Union Medical College (PUMC) Hospital, PUMC & Chinese Academy of Medical Sciences, Beijing, China;

⁵ Faculty of Hepato-Pancreato-Biliary Surgery, the Eighth Medical Center of the Chinese PLA General Hospital, Beijing, China;

⁶ Department of Hepatobiliary Surgery, Beijing ChaoYang Hospital, Capital Medical University, Beijing, China;

⁷ Senior Department of Hepatology, the Fifth Medical Center of the Chinese PLA General Hospital, Beijing, China;

⁸ Comprehensive Liver Cancer Center, the Fifth Medical Center of the Chinese PLA General Hospital, Beijing, China;

⁹ Department of General Surgery Center, Beijing Youan Hospital, Capital Medical University, Beijing, China;

¹⁰ Department of General Surgery, Xuanwu Hospital, Capital Medical University, Beijing, China;

¹¹ Department of Medical Oncology, Beijing Youan Hospital, Capital Medical University, Beijing, China;

¹² Department of Gastrointestinal Oncology, Key Laboratory of Carcinogenesis and Translational Research (Ministry of Education), Peking University Cancer Hospital & Institute, Beijing, China;

¹³ Key Laboratory of Carcinogenesis and Translational Research (Ministry of Education), Hepatopancreatobiliary Surgery Department I, Peking University Cancer Hospital & Institute, Beijing, China;

¹⁴ Department of General Surgery, Peking University First Hospital, Beijing, China;

¹⁵ Department of Hepatobiliary Surgery, Peking University People's Hospital, Beijing, China;

¹⁶ Key Laboratory of Carcinogenesis and Translational Research (Ministry of Education), Sarcoma Center, Peking University Cancer Hospital & Institute, Beijing, China;

¹⁷ Department of Hepatobiliary and Pancreatic Surgery, Qinghai Red Cross Hospital, Qinghai, China;

¹⁸ Department of Interventional Radiology, the First Medical Center of the Chinese PLA General Hospital, Beijing, China;

¹⁹ Faculty of Hepato-Pancreato-Biliary Surgery, the Sixth Medical Center of the Chinese PLA General Hospital, Beijing, China;

²⁰ Department of Interventional Therapy, Cancer Hospital of China Medical University, Liaoning Cancer Hospital & Institute, Liaoning, China;

- ²¹ Department of Radiation Oncology, Beijing Tsinghua Changgung Hospital, Tsinghua University, Beijing, China;
- ²² Faculty of Hepato-Pancreato-Biliary Surgery, the Fourth Medical Center of the Chinese PLA General Hospital, Beijing, China;
- ²³ Hepatic Surgery Center, Tongji Hospital, Tongji Medical College, Huazhong University of Science and Technology, Hubei, China;
- ²⁴ Department of Hepatobiliary Surgery, Xijing Hospital, the Fourth Military Medical University, Shanxi, China;
- ²⁵ Department of Medical Oncology, Peking University International Hospital, Beijing, China;
- ²⁶ Department of Hepatobiliary Surgery, Peking University International Hospital, Beijing, China;
- ²⁷ Department of General Surgery, Shengjing Hospital of China Medical University, Liaoning, China;
- ²⁸ Department of Surgery, The Second Affiliated Hospital, Zhejiang University School of Medicine, Zhejiang, China;
- ²⁹ Department of Gastroenterology, People's Hospital of Chongqing Hechuan, Chongqing, China;
- ³⁰ Department of Hepatobiliary Surgery, Weifang People's Hospital, Shandong, China;
- ³¹ Hepatobiliary Surgery Center, the Fifth Medical Center of the Chinese PLA General Hospital, Beijing, China;
- ³² Chinese Journal of Hepatobiliary Surgery, Beijing, China;
- ³³ Department of Hepatobiliary and Pancreatic Surgery, the Affiliated Hospital of Qingdao University, Shandong, China;
- ³⁴ Department of Hepatology and Gastroenterology, Beijing Youan Hospital, Capital Medical University, Beijing, China;
- ³⁵ Department of Liver Transplantation Center, Beijing Youan Hospital, Capital Medical University, Beijing, China;
- ³⁶ Department of Hepatobiliary Surgery, Mengchao Hepatobiliary Hospital of Fujian Medical University, Fujian, China;
- ³⁷ Department of Hepatic Surgery, Eastern Hepatobiliary Surgery Hospital, Naval Medical University, Shanghai, China;
- ³⁸ Department of General Surgery, Guangdong Provincial People's Hospital, Guangdong Academy of Medical Sciences, Guangdong, China;
- ³⁹ Department of Hepatobiliopancreatic Surgery, Sun Yat-Sen Memorial Hospital, Sun Yat-Sen University, Guangdong, China;
- ⁴⁰ Department of Hepatobiliary and Pancreatic Surgery, Peking University First Hospital, Beijing, China;
- ⁴¹ Department of General Surgery, Peking University Third Hospital, Beijing, China;
- ⁴² Department of Hepatobiliary and Pancreatic Surgery, Fujian Provincial Hospital, Fujian, China;
- ⁴³ Key Laboratory of Carcinogenesis and Translational Research (Ministry of Education), Department of Interventional Therapy, Peking University Cancer Hospital & Institute, Beijing, China;
- ⁴⁴ Department of Medical Oncology, the First Medical Center of the Chinese PLA General Hospital, Beijing, China;
- ⁴⁵ Department of General Surgery, the First Affiliated Hospital of Dalian Medical University, Liaoning, China;
- ⁴⁶ Department of Hepatobiliary Surgery and Organ Transplantation Center, The First Affiliated Hospital of USTC, Division of Life Science and Medicine, University of Science and Technology of China, Anhui, China;
- ⁴⁷ Department of General Surgery, Beijing Hospital, National Center of Gerontology; Institute of Geriatric Medicine, Chinese Academy of Medical Sciences, Beijing, China;
- ⁴⁸ Zhongshan Hospital, Fudan University, Shanghai, China;
- ⁴⁹ The Department of Hepatobiliary Surgery, the Second Affiliated Hospital of Hainan Medical University, Hainan, China;
- ⁵⁰ Department of Hepatobiliary Cancer, Liver Cancer Center, Tianjin Medical University Cancer Institute & Hospital, National Clinical Research Center for Cancer, Key Laboratory of Cancer Prevention and Therapy, Tianjin's Clinical Research Center for Cancer, Tianjin Key Laboratory of Digestive Cancer, Tianjin, China;
- ⁵¹ Department of Pathology, the First Medical Center of the Chinese PLA General Hospital, Beijing, China;
- ⁵² Department of General Surgery, Beijing Shijingshan Hospital, Beijing, China;
- ⁵³ Department of Hepatobiliary and Pancreatic Surgery, Zhongnan Hospital of Wuhan University, Hubei, China;
- ⁵⁴ Department of Hepatobiliary Surgery, the Fourth Hospital of Hebei Medical University, Hebei, China;
- ⁵⁵ Department of Gastroenterology, Beijing Chest Hospital, Capital Medical University, Beijing, China;
- ⁵⁶ Department of Radiology, the First Hospital of China Medical University, Liaoning, China;
- ⁵⁷ Department of Liver Surgery, West China Hospital, Sichuan University, Sichuan, China;
- ⁵⁸ Department of General Surgery, Tangdu Hospital, the Fourth Military Medical University, Shanxi, China;
- ⁵⁹ Department of Hepatobiliary Surgery, the First Affiliated Hospital of Guangxi Medical University, Guangxi, China;
- ⁶⁰ Institute of Hepatobiliary Surgery, Southwest Hospital, Army Medical University, Chongqing, China;
- ⁶¹ Department of Hepatobiliary Surgery, the Second Affiliated Hospital, Chongqing Medical University, Chongqing, China;
- ⁶² Department of Hepatobiliary Surgery, Qilu Hospital of Shandong University, Shandong, China;
- ⁶³ Department of Interventional Ultrasound, the Fifth Medical Center of the Chinese PLA General Hospital, Beijing, China;
- ⁶⁴ Department of Gastrointestinal Oncology, the Fifth Medical Center of the Chinese PLA General Hospital, Beijing, China;
- ⁶⁵ Department of Immunology and National Center for Biomedicine Analysis, the Fifth Medical Center of the Chinese PLA General Hospital, Beijing, China;
- ⁶⁶ Department of Transplant Surgery, Qilu Hospital of Shandong University, Shandong, China;
- ⁶⁷ Institute of Hepatopancreatobiliary Surgery, Chongqing General Hospital, Chongqing University, Chongqing, China;
- ⁶⁸ Center of Hepato Pancreato Biliary Surgery, the First Affiliated Hospital, Sun Yat-sen University, Guangdong, China;
- ⁶⁹ Department of Oncology and Hematology, the Second Affiliated Hospital of Shandong University of Traditional Chinese Medicine, Shandong, China;
- ⁷⁰ Department of Hepatobiliary and Pancreatic Surgery, the Affiliated Cancer Hospital of Zhengzhou University & Henan Cancer Hospital, Henan, China;
- ⁷¹ Department of Liver Surgery and Transplantation, Key Laboratory of Carcinogenesis and Cancer Invasion (Fudan University), Ministry of Education, Shanghai Key Laboratory of Organ Transplantation, Liver Cancer Institute, Zhongshan Hospital, Fudan University, Zhongshan Hospital, Fudan University, Shanghai, China.

SUMMARY Up to half of hepatocellular carcinoma (HCC) cases are diagnosed at an advanced stage, for which effective treatment options are lacking, resulting in a poor prognosis. Over the past few years, the combination of immune checkpoint inhibitors and anti-angiogenic targeted therapy has proven highly efficacious in treating advanced HCC, significantly extending patients' survival and providing a potential for sequential curative surgery. After sequential curative hepatectomy or liver transplantation following conversion therapy, patients can receive long-term survival benefits. In order to improve the long-term survival rate of the overall population with liver cancer and achieve the goal of a 15% increase in the overall 5-year survival rate outlined in the Healthy China 2030 blueprint, the Professional Committee for Prevention and Control of Hepatobiliary and Pancreatic Diseases of Chinese Preventive Medicine Association, Chinese Society of Liver Cancer, and the Liver Study Group of Surgery Committee of Beijing Medical Association organized in-depth discussions among relevant domestic experts in the field. These discussions focused on the latest progress since the release of the Chinese expert consensus on conversion therapy of immune checkpoint inhibitors combined antiangiogenic targeted drugs for advanced hepatocellular carcinoma (2021 Edition) and resulted in a new consensus on the modifications and supplements to related key points. This consensus aims to further guide clinical practice, standardize medical care, and promote the development of the discipline.

Keywords hepatocellular carcinoma; molecularly targeted therapy; hepatectomy; immune checkpoint inhibitors; conversion therapy

Liver cancer is a malignancy with high morbidity and mortality rates. In China, approximately 367,700 new cases of liver cancer and 316,500 liver cancer-related deaths occur annually (1). Hepatocellular carcinoma (HCC) is the predominant type of liver cancer, accounting for about 75.0-90.0% of all primary liver cancer cases (2,3). Due to the insidious onset of liver cancer, most patients present without clinical symptoms during the early stages. Consequently, 39.0% to 53.6% of patients are diagnosed with advanced HCC at their initial visit (4). In this consensus, the definition of advanced HCC aligns with the *Guidelines for Diagnosis and Treatment of Primary Liver Cancer in China (2024 Edition)* and the Barcelona Clinic Liver Cancer (BCLC) staging system. Advanced HCC is characterized by macrovascular invasion or extrahepatic metastases detected on imaging, corresponding to CNLC stage IIIa/IIIb or BCLC stage C.

Less than 30% of patients with HCC are suitable candidates for radical surgery at the time of initial diagnosis. Currently, effective curative treatments for advanced HCC remain limited, and the prognosis is generally poor (5). According to current guidelines, the treatment for advanced HCC is typically non-surgical, as radical surgery aimed at achieving a cure is rarely feasible. For patients with CNLC stage IIIa HCC, and especially those with tumor thrombi in the main trunk of the portal vein, transcatheter arterial chemoembolization (TACE) or TACE combined with systemic therapy is recommended as the preferred treatment option. Surgical resection may only be considered in very rare cases following a multidisciplinary team (MDT) discussion. For patients with CNLC stage IIIb HCC (with

extrahepatic metastases), systemic therapy and local therapy are recommended as first-line treatment options (3). The European Association for the Study of the Liver (EASL) guidelines and the BCLC staging system recommend systemic therapy as the sole treatment option for patients with BCLC stage C HCC (5,6). With advances in systemic antitumor therapies, combination regimens involving immune checkpoint inhibitors (ICIs) and antiangiogenic targeted drugs (AATDs) have demonstrated remarkable efficacy. Current guidelines have prioritized the use of ICIs combined with AATDs as the first-line treatment for advanced HCC (3,7,8). This shift in treatment paradigms not only offers improved survival benefits from systemic antitumor therapy but also opens up new possibilities for down-staging, conversion therapy, and sequential surgical interventions in patients with advanced HCC (9).

Since the publication of the *Chinese Expert Consensus on Conversion Therapy of Immune Checkpoint Inhibitors Combined with Antiangiogenic Targeted Drugs for Advanced Hepatocellular Carcinoma (2021 Edition)*, four consensus on the topic of conversion therapy have been released in China (10-13). To further advance the concept of sequential surgeries following conversion therapy, improve clinical practice, enhance the long-term survival rates of patients with advanced HCC, and promote progress in the field, the Professional Committee for Prevention and Control of Hepatobiliary and Pancreatic Diseases of Chinese Preventive Medicine Association, the Chinese Society of Liver Cancer, and the Liver Study Group of the Surgery Committee of Beijing Medical Association organized in-depth discussions among domestic experts in the field. Through comprehensive

analysis of clinical outcomes and extensive discussion of the key points of the consensus, this updated consensus has been reached.

Applicable population

This consensus applies to patients diagnosed with advanced HCC. Intended users include clinicians, nurses, technicians, as well as personnel involved in teaching and scientific research related to the diagnosis and treatment of HCC at medical facilities of all levels.

Search strategy

The consensus was reached by lead experts through searches of the databases PubMed, Web of Science, China National Knowledge Infrastructure (CNKI), and Wanfang, as well as reviews of abstracts from recent international conferences, including those of the American Society of Clinical Oncology (ASCO) and the European Society for Medical Oncology (ESMO). The search terms included "hepatocellular carcinoma," "molecularly targeted therapy," "ICI," "immunotherapy," "conversion therapy," "transarterial intervention therapy," "systemic therapy," "local therapy," and "radiotherapy." Both subject terms and free-text terms were combined to perform searches in both Chinese and English.

Description of recommendations

This consensus has been registered on the International Practice Guideline Registration for Transparency (PREPARE) Platform (registration number: PREPARE-2024CN846). During updating of the consensus, the lead expert group made preliminary revisions based on published data and clinical experience. Consensus opinions and supporting evidence were thoroughly discussed through consultations online, in writing, and offline. Feedback was incorporated into updates, followed by an expert seminar where the final draft was voted upon. Each consensus opinion was adopted with an agreement rate of 80% or more among the attending experts. The consensus applies the Oxford Centre for Evidence-Based Medicine Grading (2011 edition) to evaluate evidence levels (graded as 1~5). Recommendations are categorized as: Strong recommendation (Recommendation A); Moderate recommendation (Recommendation B); or Weak recommendation (Recommendation C) (3).

Consensus Text

1. Current treatment landscape for advanced HCC and the necessity of conversion therapy

For patients with advanced unresectable HCC, traditional

systemic therapies and local treatments, including transarterial chemoembolization (TACE), hepatic arterial infusion chemotherapy (HAIC), transarterial radioembolization, stereotactic body radiation therapy (SBRT), and ablation, as well as combination regimens involving these approaches, are commonly utilized treatment options (3).

Previous studies have shown that SBRT for primary lesions of advanced HCC can achieve an objective response rate (ORR) of up to 81.5%, with a median progression-free survival (PFS) of 4.0-6.0 months and a median overall survival (OS) of 8.0-15.4 months. The 1-, 3-, and 5-year survival rates were 36.2-56.0%, 12.4-28.0%, and 4.3-20.0%, respectively (14,15). TACE is the recommended treatment for patients with CNLC stage IIIa HCC and is also an optional treatment for some patients with CNLC stage IIIb HCC who may benefit from TACE in controlling intrahepatic tumor growth (3,16). Depending on disease severity and treatment variations, the ORR of TACE ranges from 3.9-37.9%, the median PFS is 3.6-6.3 months, and the median OS is 5.0-15.5 months. The 1-, 3-, and 5-year survival rates are 36.0-68.0%, 13.0-22.0%, and 5.0-8.0%, respectively (17-22). Compared to TACE, HAIC offers several advantages, including a lower incidence of adverse reactions, broader indications, and minimal impact on subsequent surgery, leading to its increased use in clinical practice over the past few years (23). For patients with unresectable large HCC, studies have found that HAIC achieves a better ORR than traditional TACE (24,25). Significant progress has also been made in the combined use of various non-surgical local treatments, including TACE combined with radiotherapy (26,27), TACE combined with ablation (28,29), and TACE combined with HAIC (30). These have been found to control local lesions in some patients with advanced HCC for which the treatment is indicated, thereby improving survival outcomes (16).

Over the past few years, ICIs and AATDs have achieved encouraging results in the treatment of various solid tumors. Drugs such as sorafenib, lenvatinib, donafenib, bevacizumab, pembrolizumab and atezolizumab have been confirmed to be effective in the treatment of advanced HCC (31-34). Theoretically, ICIs and AATDs can have a synergistic effect by improving the immune microenvironment and by also promoting the normalization of immune-active cell functions. Based on a large phase III randomized controlled clinical trial, ICIs combined with AATDs - as exemplified by atezolizumab plus bevacizumab, sintilimab plus a bevacizumab biosimilar, camrelizumab plus apatinib and pembrolizumab plus lenvatinib - have displayed considerable clinical efficacy in the treatment of advanced unresectable HCC: The ORR is as high as 21-30%, and the median OS is 19.2-22.1 months (31,35-37). In studies involving patients with unresectable HCC, subgroup analysis showed that the median OS has

not yet been reached (95% CI, 13.5-unreached), with a median PFS of 5.7 months (95% CI, 4.2-8.3) for Chinese patients treated with atezolizumab in combination with bevacizumab (38). Different ICI combinations, such as durvalumab plus tislelizumab and nivolumab plus ipilimumab, also yielded positive results, with an ORR of 20.1-36% and median OS of 16.4-23.7 months (39,40). Based on the survival benefits of the combination regimens, the immunotherapy based regimen, and especially the more widely used combination of an ICI and an AATD, has become the preferred first-line treatment for advanced HCC (3,8).

In addition, the exploration of local therapy plus systemic therapy in the treatment of advanced HCC is also actively being promoted. For example, the phase III EMERALD-1 study suggested that, compared to a placebo plus TACE, durvalumab plus bevacizumab plus TACE significantly prolonged PFS and increased the ORR in patients with unresectable HCC (41). However, the OS benefit still requires further follow-up for clarification. Several phase II clinical studies and real-world retrospective studies have explored local treatments such as TACE or HAIC combined with tyrosine kinase inhibitors (TKIs) (42,43), ICIs (44), or ICIs plus TKIs regimens (45-50). Those studies have shown that, according to the Response Evaluation Criteria in Solid Tumors 1.1 (RECIST 1.1), the ORR can reach 41-67.9%; according to the modified Response Evaluation Criteria in Solid Tumors (mRECIST), the ORR ranged from 54.1% to 83.3%, the median PFS ranged from 9 to 15 months, and the median OS ranged from 16.3 to 23.9 months, demonstrating stronger tumor shrinkage and survival benefits compared to either local therapy alone or systemic drug therapy alone. However, high-level evidence from randomized controlled trials is still lacking to further confirm its long-term efficacy and safety (13).

Systemic therapy, and especially ICIs combined with AATDs therapy based on high-level research evidence, has changed the treatment landscape for advanced HCC to a great extent. However, drug resistance and disease progression remain challenges that patients with advanced HCC have to face. The underlying reason for the poor overall prognosis in these patients is that neither single nonsurgical local therapies nor systemic therapies, nor a combination thereof, are radical treatments, and thus they provide limited oncological benefit. Conversion therapy for HCC refers to the use of systemic therapy, local therapy, or a multi-dimensional/multi-modal combination of both, to convert an advanced, unresectable tumor into one that is resectable, thereby providing patients with the opportunity to undergo sequential radical surgery to remove heterogeneous lesions, reduce tumor recurrence, and prolong patient survival. With advances in comprehensive treatment, the combination of ICIs plus AATDs conversion therapy and sequential surgeries for advanced HCC has, to some

extent, overcome the efficacy bottleneck, leading to improved long-term survival. As novel therapies emerge, sequential surgeries will become possible for patients with advanced HCC following successful conversion therapy using ICIs plus AATDs. A point worth noting is that conversion therapy and existing systemic therapy or local therapy are not incongruous. The key difference is that conversion therapy is the first step in the whole treatment process and successful conversion may provide patients with the opportunity for sequential surgery, which can result in greater survival benefits. Even if conversion therapy fails, patients can still receive standardized and reasonable therapies.

Consensus 1

Conversion therapy for advanced HCC has two goals: (1) surgical resectability and (2) oncological benefits (Evidence Level 2, Recommendation A).

Consensus 2

The ICI and AATD-based conversion therapy and the current systemic therapy or local therapy are not incongruous. Even if conversion therapy fails, patients can receive standardized and reasonable treatment. Therefore, the treatment paradigm of sequential surgery following conversion therapy based on a combination of ICI and AATD is recommended (Evidence Level 1, Recommendation A).

2. Current status of conversion therapy for advanced HCC

A study reviewing and analyzing clinical data on 835 patients with liver cancer suggested that patients with advanced HCC and hepatic macrovascular invasion or extrahepatic metastasis mainly received local treatment, systemic treatment, supportive treatment, or surgery; less than 10% of those patients underwent surgery, and the overall prognosis remained poor (51). Previous studies have indicated that in patients with advanced HCC who underwent liver resection, the median recurrence-free survival (RFS) after surgery is only 1.5-10.0 months, the 1- and 3-year RFS rates were 13.3-66.0% and 0.6-15.0%, respectively, and the median OS was 4.8-19.5 months, with 1- and 3-year survival rates of 28.6-50.0% and 12.5-22.7%, respectively. The 5-year survival rate was only 4.0-23.8%, which are still significantly lower than the survival rates associated with radical treatment (17,52-57).

Most advanced HCCs are not resectable. Even when direct surgical resection is performed, there are still problems such as rapid postoperative recurrence and high recurrence rates. Several studies have confirmed that advanced tumor stages are risk factors for early recurrence and poor prognosis after surgery in patients

with HCC (53,58,59). Based on considerations such as improving surgical resectability and oncological benefits and in light of the current status of systemic treatment for HCC, patients with advanced HCC are the key population for conversion therapy. Although there is still a lack of evidence from head-to-head randomized controlled studies, previous studies have suggested that immuno-targeted conversion therapy plus sequential surgeries can offer tumor-free survival and OS benefits for patients with advanced HCC and that surgical resection after conversion is an independent prognostic factor for achieving a longer OS in patients with initially unresectable HCC (60-62).

In addition, mounting evidence shows that the survival outcomes of patients with HCC who have been successfully down-staged to meet transplantation criteria are similar to those of patients who were initially eligible for transplantation. If, for example, liver transplantation is performed after patients with HCC who initially did not meet the Milan criteria are down-staged with TACE, radiofrequency ablation, radiotherapy or radioembolization, those patients could achieve similar survival benefits as those who initially met the Milan criteria and received a liver transplant. The 1-, 3-, and 5-year survival rates of the patients were 91.4% vs. 92.0%, 82.8% vs. 85.7%, and 70.4% vs. 74.1% ($p = 0.540$), respectively. The 1-, 3-, and 5-year relapse-free survival rates were 87.9% vs. 87.5%, 75.9% vs. 81.3%, 63.8% vs. 66.1% ($p = 0.667$), respectively (63). If patients with HCC who did not meet the UCSF (University of California, San Francisco) criteria are first down-staged to meet the UCSF criteria before liver transplantation, they can receive similar survival benefits as those who initially met the UCSF criteria and who received a direct liver transplant (64).

Consensus 3

Conversion therapy is mainly used to treat advanced HCC, which corresponds to CNLC stage IIIa and IIIb or BCLC stage C. Radical surgery or liver transplantation after conversion therapy may result in long survival benefits (Evidence level 2, Recommendation A).

2.1. Single-agent ICI, AATD or local conversional therapy

From individual cases and empirical conversion based on local treatment to systemic conversion based on immuno-targeted therapies, the exploration of conversion therapy for liver cancer has accelerated. The ORR for first-line single-agent ICI and first-line single-agent AATD therapy are 14.3-17% (40,65,66) and 2-18.8% (34,67-69), respectively, in advanced unresectable HCC. When monotherapy is used, the insufficient objective response and limited tumor shrinkage have restricted its

use in conversion therapy (70-72).

Local therapy is more effective in directly targeting and controlling tumor lesions, with a higher ORR and successful conversion rate compared to targeted or immune therapy alone (73). A meta-analysis showed that patients with initially unresectable HCC treated with TACE alone had an overall ORR of 44% and an overall successful conversion rate of 10% (74). In one retrospective study, HAIC for advanced HCC had an ORR of 34.9% and a conversion rate of 29.7% (75). The median RFS for concurrent chemoradiotherapy combined with HAIC yielded a conversion rate of 16.9%, a median OS of 23.0 months, and a 5-year OS of 49.6% (76). For HCC patients with main hepatic vascular invasion, radical resection following concurrent chemoradiotherapy combined with HAIC returned a successful conversion rate of 26.5%. The survival benefit of those patients was better than that of patients undergoing direct hepatectomy, with median RFS time of 32.0 months vs. 3.0 months ($p = 0.002$) and 1-, 3-, and 5-year RFS of 57.7% vs. 16.7%, 38.5% vs. 11.1%, and 11.5% vs. 5.6%, respectively ($p = 0.004$). The 1-, 3-, and 5-year relapse-free survival rates were 57.7% vs. 16.7%, 38.5% vs. 11.1%, and 11.5% vs. 5.6%, respectively ($p = 0.004$) (77). The conversion rate for patients with initially unresectable HCC receiving TACE combined with HAIC reached 48.8%, which was higher than that for TACE alone, and PFS was superior to TACE alone, too. However, there were no significant differences in OS (30). In general, compared to that of targeted monotherapy (e.g., sorafenib and lenvatinib), local therapy as exemplified by TACE and HAIC has more potential of successful conversion, but its clinical efficacy is still not satisfactory.

2.2. ICI plus AATD conversion therapy

As the ICI combined AATD regimen has become the preferred treatment recommendation for advanced unresectable HCC, combined regimens have gradually become the mainstream approach in the exploration of conversion therapy.

At present, immuno-targeted conversion therapy for advanced HCC is mostly examined in small samples or retrospective clinical studies. The patients studied are mainly BCLC stage C, with an ORR of 23.3-53.1% and a successful conversion rate of 15.9-55.4% (61,62,78-81). Professor Shichun Lu reported the results of a study of 100 patients with HCC and portal vein tumor thrombosis who underwent surgery (82). Of these, 36 patients underwent immuno-targeted conversion therapy and sequential surgery, while 64 patients underwent direct surgery. The median follow-up was 27.9 months. Propensity score matching indicated that the 2-year cumulative survival rate was 73.3% vs. 38.2% in patients receiving sequential surgery following conversion therapy and in patients receiving surgery directly, while

the 2-year relapse-free survival rate was 47.9% vs. 16.7%. The risk of postoperative recurrence was reduced by 76% (HR: 0.24, 95% CI: 0.123 to 0.467, $p < 0.001$) and the risk of death was reduced by 77% (HR: 0.23, 95% CI: 0.121 to 0.638, $p = 0.003$).

In a Phase II clinical study, 56 patients with advanced HCC and large vessel tumor thrombosis received treatment with lenvatinib plus a programmed death-1 (PD-1) inhibitor. According to mRECIST and RECIST 1.1 assessments, the ORR was 53.6% and 44.6%, respectively. According to imaging evaluation, the successful conversion rate was 55.4%. Surgical resection was performed in 21 cases (37.5%) after conversion. The median PFS of 56 patients with advanced HCC was 8.9 months, the 1-year PFS rate was 46.2%, the median OS was 23.9 months, and the 1-year survival rate was 72.8%. Multivariate Cox regression analysis indicated that successful conversion was an independent protective factor for both PFS (HR: 0.29, 95% CI: 0.15-0.57, $p < 0.001$) and OS (HR: 0.31, 95% CI: 0.15-0.66, $p = 0.002$) (61).

Another study reported the long-term efficacy of immuno-targeted conversion therapy and sequential radical resection in 100 patients with initially unresectable HCC, who underwent 3 to 28 cycles of immuno-targeted conversion therapy (83). The 1-, 3-, and 5-year cumulative survival rates were 98.0%, 83.1%, and 74.5%, respectively. The 1-, 2- and 3 -year recurrence-free survival rates were 67.5%, 54.8% and 49.6%, respectively. Both rates were significantly better than the 5-year survival rate of a historical survival data at the same stage and were not inferior to the 5-year survival rate of a cohort with a historical data of early-stage liver cancer who underwent surgical resection (60%) (57).

Therapies such as HAIC and TACE are invasive procedures that are performed during hospitalization. In contrast, the administration of ICIs combined with AATDs is more convenient, as it can be done in a day-care ward or even at home. The incidence of severe adverse events is low, and most adverse reactions can be managed with drug cessation or simple supportive treatment, leading to recovery. Notably, the relatively high ORR of ICIs combined with AATDs may improve the conversion rate for advanced HCC, enabling more patients to undergo potentially curative surgery.

Consensus 4

ICIs plus AATDs is the recommended approach for conversion therapy for advanced HCC. Specific regimens include atezolizumab plus bevacizumab, camrelizumab plus apatinib, sintilimab plus bevacizumab biosimilar, and pembrolizumab plus lenvatinib. The combination regimen with a higher ORR may have a higher potential for successful conversion of advanced HCC, and hence is more

recommended (Evidence level 2, Recommendation B).

Consensus 5

For patients with advanced HCC undergoing ICI plus AATD conversion therapy, the following criteria must be met: (1) Child-Pugh class A liver function; (2) Eastern Cooperative Oncology Group (ECOG) performance status (PS) score of 0 or 1; (3) 18-75 years of age; (4) Expected survival time longer than 3 months; (5) No history of gastrointestinal hemorrhage within the past 6 months; For patients who do not meet the above criteria, exploratory treatment may still be considered based on the individual situation (Evidence level 2, Recommendation B).

Considering the onset time of combined immunotherapy, risk of progression, and patient compliance and based on the interval of post-treatment evaluation in phase III clinical studies, treatment response should be evaluated every 3 cycles (6-8 weeks after the start of treatment) of combination therapy (36). Depending on changes in the patient's condition, the evaluation interval can be shortened or extended as appropriate.

Clinical studies have reported that, for unresectable HCC, the median time to response assessed by mRECIST was 2.7 months (range 1.2 to 11.8) for pembrolizumab plus lenvatinib and 1.9 months (range 1.1 to 9.2) for camrelizumab plus apatinib (84). Hence, although the median response time for immuno-targeted therapy for unresectable HCC is 2 to 3 months, some patients may require a longer period to respond. In clinical research and practice of conversion therapy, there have also been cases of successful conversion after nearly one year of treatment. As reported by Professor Tianqiang Song, the conversion time was 2 to 15 months, and the median conversion time was 4 months (85). In the Phase II prospective clinical study conducted by Professor Shichun Lu, the median time from the start of conversion therapy to surgery was 109 days (ranging from 77 to 219 days), with successful conversion occurring in most patients within 5 cycles of immuno-targeted therapy (61). Given that immuno-targeted therapy has become the standard treatment for advanced HCC, the extension of the evaluation window will not affect patients' ability to accept reasonable treatment. Therefore, the evaluation window can be appropriately extended for patients for whom surgery is not indicated so that they have more opportunity to undergo radical surgery.

Consensus 6

The response to conversion therapy should be evaluated once every three cycles of conversion therapy, and the intervals may be adjusted based on the patient's condition. Appropriate extension of the evaluation window may increase the chances

of performing a radical resection to some extent (Evidence level 2, Recommendation B).**2.3. Value of synergistic local treatment based on ICIs plus AATDs**

Local treatment may have a synergistic effect with systemic treatment. Using TACE as an example, AATDs can inhibit neovascularization in HCC treated with TACE, thus further enhancing the therapeutic effects of TACE. After TACE treatment, the expression of cytotoxic T-lymphocyte-associated antigen 4 (CTLA-4) and programmed death-ligand 1 (PD-L1) increases, weakening the immune response; ICIs can block CTLA-4 and PD-1, thereby restoring the anti-tumor action of the immune system (86,87).

Some studies have reported that the successful conversion rate of ICIs plus AATDs combined with local therapy in patients with initially unresectable HCC is 22-60%, though the long-term survival outcomes still need to be confirmed by extended follow-up (88-90). Due to the lack of head-to-head comparative studies and differences in patient characteristics, definitions of conversion success, and resectability criteria across various studies on conversion, whether immuno-targeted therapy combined with local treatment can improve long-term survival benefits while increasing the likelihood of conversion still needs to be further validated.

In addition to efficacy, safety and pharmacoeconomics are also important factors affecting the selection of conversion therapy. Based on clinical practice, an increase in treatment intensity inevitably increases the risk of treatment-related adverse events. Local and systemic therapies each have specific contraindications. For example, TACE should be used with caution in patients with HCC and main portal vein or left and right branch tumor thrombus. Due to blocked portal blood flow into the liver, TACE may aggravate liver ischemia and lead to liver failure. Additionally, combining drug therapy with local treatment makes it more complicated to identify the drug efficacy. Therefore, when deciding on conversion therapy, efficacy and safety should be balanced in accordance with the actual circumstances of patients to ensure their quality of life, reduce their medical burden, and increase the objectivity of efficacy evaluation. According to clinical studies, about 70% of patients who were successfully converted used immuno-targeted therapy without additional local therapy (62,83). Considering factors such as efficacy and safety, a progressive combined conversion strategy can be adopted, that is, the ICI and AATD therapy is the first-line conversion regimen, used to identify patients sensitive to immuno-targeted therapy, who can then continue with the initial regimen alone. For some patients who respond poorly to immuno-targeted therapy (no successful conversion or exhibiting signs of disease progression), local treatment should be added to intensify

therapy, promote tumor antigen release, enhance anti-tumor immunity, and improve the speed and success rate of conversion therapy (91).

Consensus 7

Immune-targeted therapy is the basis of the treatment paradigm of sequential surgery following conversion therapy. For patients who have a poor response to immune-targeted therapy (Progressive Disease or Stable Disease), adding local treatment under the guidance of a multidisciplinary team may help accelerate the conversion process and increase the conversion rate. (evidence level 2, recommendation B).

3. Key issues with conversion therapy involving ICIs combined with AATDs

Various studies on sequential surgery for advanced HCC have gradually been compiled, and clinical efficacy has significantly improved. The immuno-targeted conversion therapy and sequential surgery model in particular has evolved from early case-based exploration into a systematic approach to conversion, with significant improvements in conversion efficiency, and that model may become the mainstream paradigm for radical treatment of advanced liver cancer. However, several clinical issues with the immuno-targeted conversion therapy and sequential surgery model still need to be addressed, including the determination of surgical indications for conversion therapy, the optimal timing of surgery, key procedures and perioperative management after conversion therapy, as well as the evaluation of prognosis and management of follow-up after conversion therapy.

3.1. Value of and indications for sequential surgeries following immuno-targeted conversion therapy

No prospective, head-to-head randomized controlled studies have compared the continuation of the initial systemic or local treatment after successful conversion and sequential surgeries. Therefore, more high-level evidence is needed to ascertain the value of sequential surgeries following conversion therapy.

One study involving patients with initially unresectable HCC who had a radiological or clinical complete response after conversion therapy suggested that the 3-year cumulative survival (88.1% vs. 87.9%, $p = 0.89$) and PFS (27.8% vs. 40.8%, $p = 0.34$) were comparable between the watch-and-wait group and the surgical resection group (92). In another study of 144 patients with initially unresectable HCC who met resection criteria after immuno-targeted therapy plus TACE therapy, patients with a partial response who underwent surgeries had a better OS and PFS than those who did not (93). However, the benefit of surgeries was

not observed in patients with a complete response. Some findings have also suggested that clinical complete response does not equate to pathological complete response, and residual surviving cancer cells may still lead to a high rate of recurrence, so the necessity of post-conversion surgery should be emphasized (94,95). At present, an increasing number of studies have confirmed the survival advantages of sequential surgeries after conversion therapy compared to continued local and/or systemic therapy. A multicenter, real-world retrospective study involving 405 patients with intermediate-to-advanced liver cancer compared the outcomes of successful conversion surgery with continued local and systemic therapy (96). Multivariate Cox regression analysis indicated that surgery was a predictive factor for OS but not for event-free survival. Similarly, a multicenter retrospective study of 150 patients with CNLC stage IIIb HCC found that patients who underwent surgery after successful immunotargeted conversion therapy had a longer survival than those who did not (97). Surgery was identified as an independent predictive factor for survival (HR = 0.195, 95% CI: 0.061-0.626, $p = 0.006$), but there were no significant differences in PFS between the two groups. In a study of 101 patients with unresectable HCC by Professor Huichuan Sun, median follow-up was 21.5 months. Multivariate Cox regression analysis indicated that liver resection after conversion was an independent predictive factor for patient survival (HR = 0.050, 95% CI: 0.007-0.365, $p = 0.003$) (60).

In addition, surgical intervention reduces the long-term use of drugs, lowering the risk of adverse drug reactions and drug resistance. Pathological examination of surgically excised specimens helps to evaluate the efficacy of conversion therapy and assess patient prognosis, thereby guiding postoperative adjuvant treatment. Therefore, growing evidence from real-world and Phase II clinical studies on conversion, along with breakthroughs in long-term patient survival, has increasingly revealed the value of surgery in conversion therapy.

Consensus 8

Considerations for surgical resection after conversion therapy:

(1) Radical tumor resection is the key for disease cure; (2) Surgical intervention may shorten the time of ICIs and AATDs use to a certain degree, thereby reducing drug resistance and drug-related adverse reactions; (3) Pathological examination of the tumor helps to confirm the effectiveness of conversion therapy and guide the subsequent adjuvant therapy (Evidence level 2, Recommendation A).

Sequential surgeries should not be considered for patients with disease progression following conversion therapy. Radical surgery may be indicated when patients

are down-staged to CNLC stage I or BCLC stage A after conversion therapy. When selecting radical resection, the patient must also meet the general surgical criteria for technically resectable surgery (93), including Child-Pugh class A or B liver function and adequate residual liver volume. Due to the presence of background liver disease and the potential for liver tissue damage caused by ICIs and AATDs, the standard residual liver volume after surgery can be moderately increased to $\geq 35\%$ of the standard liver volume for non-cirrhotic patients and $\geq 45\%$ for cirrhotic patients. The 15-min retention rate of indocyanine green (IOG) should be $< 20\%$. The hepatic vascular inflow and outflow tract should be intact and blood flow should be satisfactory after surgery. The structure of the biliary tract should be intact and drainage should not be obstructed. The ECOG-PS score should be 0-1, and the American Society of Anesthesiologists (ASA) rating should be no higher than III.

When the liver tumor is converted a technically unresectable to a technically resectable state, that is, the above general surgical criteria have been met, and the benefits by imaging evaluation have been obtained after the conversion treatment (such as a partial response according to mRECIST). Then, if no further response by imaging evaluation can be obtained after two or more consecutive evaluation cycles, and the tumor thrombus or extrahepatic metastatic lesions can be resected simultaneously, surgical resection or superimposed local treatment (including ablation, intervention, radiotherapy, etc.) can also be considered, even if the tumor has not yet been down-staged to CNLC stage I or BCLC stage A. In cases of liver decompensation, liver transplantation may be an option (98). Complete resection of the tumor may eliminate the potential impact of tumor heterogeneity on prognosis, however, tumor debulking surgery is not recommended.

Consensus 9

For advanced HCC with downstaging and/or potentially resectable tumors after conversion therapy, radical surgery is recommended. The following technical criteria must be met for sequential radical resection after conversion therapy: (1) Child-Pugh class A or B liver function; (2) Adequate future liver remnant; (3) ICG 15-min retention rate $< 20\%$; (4) Preservation of adequate vascular and biliary inflow/outflow after surgery; (5) The bile duct structure is intact with unobstructed drainage postoperatively; (6) ECOG-PS score of 0-1; (7) ASA classification no higher than grade III. (Evidence level 2, Recommendation B).

Consensus 10

Conversion therapy is considered successful and radical resection can be performed when patients with BCLC stage C HCC and extrahepatic metastases meet

the following conditions: the extrahepatic lesions are no longer active according to imaging, or the reduced and/or inactive extrahepatic lesions are deemed resectable (Evidence level 3, Recommendation B).

3.2. Response to conversion therapy and related evaluations

3.2.1. Evaluation of general status and routine laboratory results

Evaluation of general status includes changes in clinical symptoms, mental state, physical condition, appetite, and weight, which can be assessed *via* models such as ESGO-PS score. Routine laboratory results include the complete blood count, liver and kidney function tests, and coagulation profiles.

3.2.2. Imaging evaluation

Tumor response is evaluated using contrast-enhanced imaging (enhanced MRI or CT), with reference primarily to RECIST 1.1, mRECIST, and the Liver Imaging Reporting and Data System (LI-RADS) 2018 Edition developed by the American College of Radiology. RECIST 1.1 uses changes in tumor diameter as the basis for evaluating treatment response, while mRECIST evaluates changes in tumor enhancement during the arterial phase. mRECIST and LI-RADS have similar criteria for assessing the treatment response in HCC.

Lesion necrosis is the basis for the gradual absorption and disappearance of tumors after treatment. Necrosis occurs first, while lesion absorption and disappearance proceed more slowly. Yu *et al.* (99) systematically reviewed 23 studies ($n = 2,574$) on molecularly targeted therapies for HCC. According to mRECIST, patients with an effective treatment response had a significantly better OS than those without such a response. However, RECIST 1.1 failed to indicate significant differences in OS between responders and non-responders. Similarly, Jung *et al.* (100) reported that in patients with advanced HCC who received TACE plus radiotherapy, those with an effective treatment response according to mRECIST had a significantly better OS than did those without such a response. After tumor necrosis, significant histological and biological changes occur, meaning that necrotic lesions should no longer be considered for tumor staging or prognosis. Therefore, mRECIST is more appropriate for imaging evaluation of the response to conversion therapy.

Arizumi *et al.* (101) reported that patients with advanced HCC treated with sorafenib had a significantly higher median OS when their tumors decreased or completely disappeared in arterial phase enhancement compared to patients with no change in enhancement (19.9 months *vs.* 6.0 months, $p < 0.001$). This suggests that decreased arterial phase enhancement could serve as

an early indicator of treatment effectiveness. In clinical practice, decreased or absent arterial phase enhancement appears earlier than a reduction in tumor size or tumor disappearance, so arterial phase enhancement is a suitable imaging marker for assessing the treatment response in advanced HCC. It helps determine the optimal timing for radical surgery while reducing adverse effects and drug resistance from prolonged local or systemic therapy.

Among the imaging techniques commonly used in diagnosing HCC, MRI offers unique advantages by providing non-invasive data such as diffusion-weighted imaging (DWI). DWI-based diffusion restriction features have been widely used in the qualitative diagnosis of primary tumors and tumor thrombi (102,103). During DWI, water molecule diffusion in active tumor lesions is restricted, resulting in lower apparent diffusion coefficient (ADC). After successful treatment and tumor necrosis, water molecule diffusion is restored, leading to increased ADCs (104,105). In a study by Lu *et al.* (106), after 6 months of radiofrequency ablation in patients with HCC, the ADC value of necrotic tumor lesions increased from $1.2 \times 10^{-3} \text{ mm}^2/\text{s}$ before treatment to $1.5 \times 10^{-3} \text{ mm}^2/\text{s}$ six months after treatment.

^{18}F -fluorodeoxyglucose positron emission tomography and computed tomography (18F-FDG PET-CT) can be used to evaluate the treatment response of extrahepatic metastases. The primary criterion for determining tumor necrosis is the absence of increased contrast agent uptake (107).

A study involving 20 patients with advanced HCC treated with PD-1 inhibitors and lenvatinib found that the tumor-to-normal liver standardized uptake value ratio (TLR) was correlated with the pathological treatment response (108). Another study of 28 patients with advanced HCC receiving immuno-targeted conversion therapy found that the maximum standardized uptake value and TLR changes were more pronounced in the major pathological response group than in the non-major pathological response group (109). TLR changes demonstrated a strong predictive value for a major pathological response.

Consensus 11

The mRECIST criteria are more suitable for the radiologic assessment of the response of advanced HCC to conversion therapy. Contrast-enhanced MRI offers advantages in radiologic assessment. The complete disappearance of arterial phase enhancement and the absence of restricted diffusion can serve as imaging features with which to evaluate complete necrosis of tumor lesions after conversion therapy. The complete disappearance of arterial phase enhancement is considered to be a decisive feature. 18F-FDG PET-CT is another choice for assessment of the treatment response of extrahepatic metastases (Evidence level 2, Recommendation B).

3.2.3. Evaluation of tumor-related blood markers

In addition to imaging studies, changes in blood tumor markers are important indicators with which to evaluate the objective response to conversion therapy. Shao *et al.* (110) reported that in patients with advanced HCC receiving ICI monotherapy, early responders in terms of serum alpha-fetoprotein (AFP) levels (defined as a > 20% reduction in serum AFP within 4 weeks of starting treatment) had a significantly higher ORR compared to early non-responders (73% vs. 14%, $p < 0.001$). Moreover, early responders had a longer median OS (28.0 months vs. 11.2 months, $p = 0.048$) and median PFS (15.2 months vs. 2.7 months, $p = 0.002$). Normalization of AFP levels following immuno-targeted therapy has been associated with improved survival, while patients with post-treatment AFP levels > 20 µg/L face an increased risk of postoperative recurrence (111). In a retrospective study of patients with advanced HCC treated with a combination of TKI and PD-1 inhibitors, imaging assessment according to mRECIST and a decrease in AFP to the normal range predicted a pathological complete response, with a sensitivity of 91.7%, a specificity of 84.6%, and an overall prediction accuracy of 88.0% (112). Sun *et al.* (113) found that after 6 weeks of PD-1 inhibitor treatment, a reduction of > 50% in abnormal protein induced by vitamin K absence/antagonist-II (PIVKA-II) and AFP was associated with a higher ORR, as well as a longer PFS and OS. Additionally, a retrospective study of patients with advanced HCC treated with nivolumab monotherapy found that patients with a partial or complete response had a significantly lower neutrophil-to-lymphocyte ratio (NLR) and platelet-to-lymphocyte ratio (PLR) after treatment compared to those with stable or progressive disease (114).

Other tumor liquid biopsy markers, including circulating tumor DNA (ctDNA), circulating tumor cells (CTCs), cell-free DNA (cfDNA), and soluble programmed death-ligand 1 (sPD-L1), have shown potential in predicting the efficacy of immuno-targeted therapy. However, the current lack of large-scale clinical trial data corroborating these markers means that their clinical use needs to be studied further.

Consensus 12

For patients with pre-treatment positive serum alpha-fetoprotein (AFP) and PIVKA-II, a significant decrease in AFP and/or PIVKA-II levels often suggests an effective response to conversion therapy. Reduction and long-term maintenance of normal levels of AFP and/or PIVKA-II may indicate complete necrosis of the tumor tissue (Evidence level 3, Recommendation B).

3.3. Key points of surgical resection and perioperative complications after conversion therapy

The functional liver volume after conversion therapy for advanced HCC can be accurately measured using radiological techniques. The percentage of functional liver volume with respect to standard liver volume can also be calculated. In addition, digital imaging software is now available for 3D reconstruction of the liver, which can help with an accurate preoperative measurement of functional liver volume and the facilitation of reasonable surgical planning (115,116).

Consensus 13

Changes in the functional liver volume after conversion therapy can be assessed with a radiological examination. Surgical procedures can be planned based on 3D image reconstruction. (Evidence level 2, Recommendation A).

The key technical features of surgical resection after conversion therapy include resection of a large volume of the liver, a negative resection margin and adequate future liver remnant, resection of macrovascular tumor thrombi in the preserved liver, reconstruction of hepatic vessels and biliary tracts in the preserved liver, and simultaneous resection of extrahepatic metastases. Since surgical procedures are relatively complex, they should be performed at qualified facilities.

Some studies have shown that sequential resection after conversion therapy is more challenging than direct resection. There are potential complications such as increased blood loss, longer operating time, and more postoperative complications. However, accurate preoperative assessment can ensure the safety of the surgery (117). In a prospective cohort study by Professor Shichun Lu, 100 patients who underwent surgery after conversion therapy had no uncontrolled Grade 3 or higher drug-related adverse events before surgery, and R0 resection was achieved in all of them. Despite requiring procedures such as large-volume liver resection, a high rate of portal vein reconstruction, and extensive lymph node dissection, no patients experienced Clavien-Dindo Grade IIIb or higher complications postoperatively. Moreover, these surgeries did not increase the risk of perioperative mortality (61,62,83,118). Although surgery after conversion therapy for advanced HCC is more complex, it remains generally safe and feasible.

Consensus 14

Surgery can be safely performed after advanced HCC is down-staged. However, Surgical difficulty may increase and should be performed at experienced facilities (Evidence Level 3, Recommendation B).

3.4. Postoperative pathological evaluation

There is mounting evidence regarding the correlation between preoperative and postoperative imaging, the

pathological response to treatment, and prognosis. The prognostic value of a pathological response to treatment has also been reported. Studies have found that achieving a pathological complete response (pCR) to systemic therapy is associated with an improved RFS in patients with advanced HCC (60). For HCC, however, the threshold value for predicting survival and stratifying prognosis based on the ratio of viable tumor cells (RVTCs) remains to be established. Based on pathological evaluations of HCC specimens from patients who underwent conversion therapy and sequential surgery, Professor Shichun Lu's team found that patients with a pCR had a better RFS and OS compared to those without a complete response. When 15% was used as the optimal threshold for RVTCs to predict prognosis using receiver operating characteristic (ROC) curve analysis, patients with an RVTCs \leq 15% had a better RFS and OS compared to those with an RVTCs $>$ 15%. Thus, RVTCs can serve as a reference for prognostic evaluation and an aid in postoperative adjuvant treatment decision-making (119).

Accurate pathological evaluation must be based on standardized specimen collection. Tumor specimens often have extensive necrosis and regional viable tumor cells, so the surgical team should mark the superior and inferior poles of the tumor specimen after resection using surgical sutures or other methods. The anatomical relationship of the tumor specimen and areas where viable tumor cells are likely to be found should be indicated as much as possible, and these markings should be noted on the pathology request form for the pathologist's reference. For patients who undergo thrombectomy or lymph node dissection, the removed tumor thrombi should be marked and submitted with the superior and inferior poles clearly identified. The tumor can be dissected along the thrombus path for marking, and lymph node specimens should be numbered and submitted for inspection. All visible satellite nodules and tumor thrombi should be evaluated during pathological sampling. For specimen fixation and collection, relevant guidelines should be followed (3,119).

Consensus 15

Pathological examination of the excised specimen is an important indicator of the efficacy of immuno-targeted conversion therapy and patient prognosis. A higher level of remission may suggest a better prognosis and can also guide postoperative adjuvant treatment. To improve accuracy, attention should be paid to the standardization of specimen collection, labeling, and submission for examination (Evidence Level 3, Recommendation B).

3.5. Perioperative pharmacological treatment

There is currently no consensus on whether ICIs and

AATDs should be discontinued prior to hepatectomy (120,121). ICIs may induce immune-related inflammation in the liver, potentially increasing liver fragility. AATDs may increase the risk of bleeding during hepatectomy and impair tissue repair, leading to delayed healing of surgical wounds and incisions. To ensure surgical safety, the timing of AATD discontinuation should be determined based on the drug's half-life. For example, the half-life of lenvatinib is 28 hours, the half-life of sorafenib is 25-48 hours, and the half-life of bevacizumab is 18-20 days. Therefore, the advisable approach is to stop the TKI 3-7 days before surgery and to discontinue bevacizumab 4-6 weeks prior to the procedure. There is currently no evidence suggesting that the timing of ICI discontinuation is related to surgical safety, and ICI discontinuation can be synchronized with the cessation of AATD.

Mounting evidence has indicated that Immunotherapy based combination regimens are promising options for postoperative adjuvant therapy in patients with HCC (122-125). However, standardized treatment protocols for systemic adjuvant therapy have yet to be established. A phase III clinical trial (IMbrave 050) evaluated the efficacy and safety of adjuvant treatment with atezolizumab plus bevacizumab versus active surveillance in patients with HCC who were at high risk for recurrence after surgical resection or ablation (122,126). Results indicated that the combination regimen reduced the risk of recurrence by 28% but did not indicate a benefit in OS, with grade 3-4 treatment-related adverse events occurring at a rate of 34.9% in the combination regimen group. Professor Shuqin Cheng evaluated the efficacy and safety of sintilimab monotherapy as an adjuvant treatment for patients with HCC and microvascular invasion. They reported that sintilimab monotherapy significantly improved RFS compared to active surveillance, with a median RFS of 27.7 months versus 15.5 months. However, the benefit in OS needs to be verified with a longer follow-up. The incidence of grade 3-4 treatment-related adverse events in the sintilimab group was 12.4% (123). A prospective multicenter cohort study investigated the efficacy of immunotherapy or immunotherapy combined with other adjuvant treatments versus no adjuvant treatment in patients with HCC who were at high risk for recurrence (124). Results indicated that immunotherapy or immunotherapy combined with other adjuvant treatments could prolong RFS. Additionally, several studies have noted the preliminary efficacy of immunotherapy alone or in combination with targeted therapy as adjuvant treatment. Phase III clinical trials, such as KEYNOTE-937 (NCT03867084), CheckMate 9DX (NCT03383458), JUPITER 04 (NCT03859128), and EMERALD-2 (NCT03847428), to evaluate these strategies are still ongoing.

For patients who have successfully undergone conversion immunotherapy followed by sequential

surgery, conversion therapy has been shown to be effective. Given that the current standards for postoperative adjuvant therapy have not been fully established, part or all of the original treatment regimen is generally adopted in clinical practice for postoperative adjuvant therapy to treat patients who have undergone conversion therapy followed by surgical resection (10,12). Professor Shichun Lu initiated systemic adjuvant therapy 1 month after surgery based on pathological findings from resected samples following conversion therapy. The key points of this strategy are as follows: If a pathological examination reveals no residual viable tumor cells in the resected specimen, indicating a complete pathological response, the original ICI treatment is continued for 6 months. If residual viable tumor cells are $\leq 50\%$, indicating a partial pathological response, the original ICI treatment is continued in combination with an AATD for 6-12 months. If $> 50\%$ of residual viable tumor cells are present, or if the pathological examination detects new lesions that were not seen on imaging, indicating no response to treatment, the treatment regimen should be adjusted based on pathological and genetic findings. A study involving 47 patients with initially unresectable HCC who underwent immuno-targeted therapy and sequential resection followed by adjuvant therapy found that, after treatment, these patients met the criteria for discontinuing adjuvant therapy and remained free of recurrence thereafter, with a median follow-up of 32 months. The cumulative survival rates at 1 and 3 years were 97.7% and 90.7%, respectively, while the RFS rates 1 and 3 years after surgery were 91.0% and 71.3%, respectively, with a median RFS of 40 months. During postoperative adjuvant therapy, no grade 3 or higher adverse events were reported, although 9 patients discontinued therapy because of adverse events (127). Moreover, for patients with advanced HCC who have undergone successful conversion therapy followed by sequential resection, adopting an adjuvant treatment strategy based on results of a postoperative pathological examination may lead to postoperative recurrence rates comparable to those of patients with a low rate of recurrence undergoing primary curative resection.

Consensus 16

TKIs should be discontinued 3-7 days before hepatectomy and bevacizumab should be discontinued 4-6 weeks before surgery, while ICIs may be discontinued concurrently with AATDs. ICIs alone or ICIs plus AATDs should be continued for 6-12 months after surgery based on specific postoperative pathology results (Evidence Level 3, Recommendation C).

3.6. Management of adverse reactions

Adverse reactions are assessed based on the patient's

subjective descriptions, along with indicators such as electrocardiograms, chest X-rays, thyroid function tests, blood tests, myocardial enzymes, urinalysis, and liver function tests. Common adverse reactions related to immunotherapy mainly include the following: (1) Skin: Rash, mucositis; (2) Cardiovascular: Hypertension, immune myocarditis; (3) Gastrointestinal: Nausea, vomiting, diarrhea, colitis; (4) Endocrine: Thyroiditis, hypothyroidism, hyperthyroidism; (5) Pulmonary: Immune pneumonitis; (6) Renal: Renal insufficiency; and (7) Liver: Elevated transaminases, liver dysfunction (128,129).

Monitoring liver transaminase and bilirubin levels is important. When transaminase levels rise to less than 3 times the upper limit of normal (ULN), ICI treatment can continue. When transaminases increase to 3-5 times the ULN (excluding 5 times the ULN), ICI treatment may continue based on individual circumstances, in conjunction with prednisone therapy at a dose of $0.5\text{-}1.0\text{ mg}\cdot\text{kg}^{-1}\cdot\text{d}^{-1}$. If transaminase levels rise to 5-20 times the ULN (excluding 20 times the ULN), ICI treatment may continue based on individual circumstances, while prednisone therapy should be increased to $1\text{-}2\text{ mg}\cdot\text{kg}^{-1}\cdot\text{d}^{-1}$. If transaminase levels exceed 20 times the ULN, ICI treatment should be permanently discontinued, and prednisone therapy at $1\text{-}2\text{ mg}\cdot\text{kg}^{-1}\cdot\text{d}^{-1}$ may be administered.

Special attention should be paid to cases where both transaminase and bilirubin levels are elevated. When bilirubin increases to 1-2 times the ULN, ICI treatment may continue based on individual circumstances, in conjunction with prednisone therapy at $1\text{-}2\text{ mg}\cdot\text{kg}^{-1}\cdot\text{d}^{-1}$. If bilirubin increases to 3-4 times the ULN, ICI treatment should be permanently discontinued, and prednisone therapy at $1\text{-}2\text{ mg}\cdot\text{kg}^{-1}\cdot\text{d}^{-1}$ should be administered. If necessary, other immunosuppressive agents may be used.

Due to differences in their target mechanisms and inhibition profiles, AATDs may cause different adverse reactions. Common adverse events associated with TKIs include hypertension, diarrhea, hand-foot syndrome, fatigue, anorexia, rash, proteinuria, liver dysfunction, and hypothyroidism. Unlike liver adverse reactions related to immunotherapy, liver damage caused by TKIs tends to resolve relatively readily with a reduced dose or discontinuation and symptomatic treatment. Common adverse reactions to monoclonal AATDs such as bevacizumab include hypertension, fatigue, diarrhea, or abdominal pain. These are more likely to cause severe bleeding compared to TKIs and ICIs, so the bleeding risk should be assessed and monitored more closely during clinical use (130,131).

Previous data showed that, according to the Common Terminology Criteria for Adverse Events (CTCAE) version 5.0, the ICI plus TKI regimen had an incidence of treatment-related adverse reactions of 89.3%, with 42.9% of these being grade 3 or higher (61). There are

4 main levels of the management of severe adverse reactions during immuno-targeted conversion therapy: dose adjustment, discontinuation of the drug, permanent cessation of the drug, and cessation of all drugs and local treatment. Combining different drugs and local therapies may lead to overlapping adverse reactions, increasing the likelihood of treatment discontinuation. During immuno-targeted conversion therapy, regular and timely assessments need to be performed, management needs to be stringent, and patients need to complete the prescribed treatment regimen while minimizing the risk of severe treatment-related complications or death. In most cases, adverse reactions can be effectively alleviated or managed with symptomatic treatment if they are properly prevented. Specific management principles for adverse reactions can be found in the NCCN Guidelines for Management of Immune-related Toxicities and the relevant domestic consensus (129,132).

Consensus 17

Most adverse reactions associated with immuno-targeted conversion therapy are controllable and they resolve spontaneously or only require

symptomatic treatment. The treatment principles for adverse reactions are as per the NCCN or domestic clinical practice guidelines for management of immunotherapy-related toxicities (Evidence Level 2, Recommendation B).

3.7. Collaboration by and the value of multidisciplinary teams in conversion therapy

Unlike simple systemic or local treatments, conversion therapy for HCC includes a wider range of therapeutic approaches and involves multiple disciplines, requiring more multidisciplinary team collaboration. Advanced HCC remains a highly heterogeneous cancer, with differences in tumor biological characteristics between individuals. Additionally, factors such as the patient's general condition, risk factors, etiology, tumor burden, and comorbidities individually affect treatment decisions. Key factors contributing to the long-term survival benefits of conversion therapy include the effective tumor shrinkage and embolization achieved by combination therapy, long-term survival benefits from immunotherapy, the thoroughness of surgical resection, and a standardized chronic disease management model

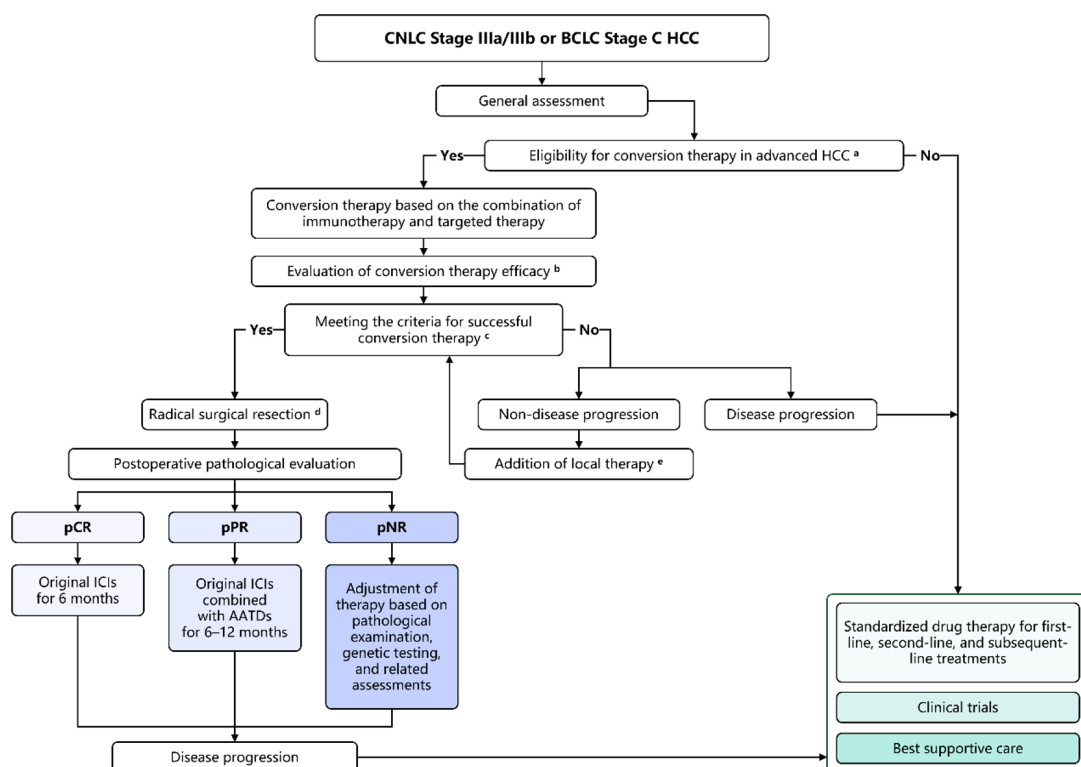


Figure 1. Sequential surgery following Immuno-targeted conversion therapy for advanced HCC. CNLC: China Liver Cancer Staging system. BCLC: Barcelona Clinic Liver Cancer staging system. pCR: Pathological complete response (no residual viable tumor cells in the resected specimen). pPR: Pathological partial response ($\leq 50\%$ residual viable tumor cells in the resected specimen). pNR: Pathological no response ($> 50\%$ residual viable tumor cells or new lesions identified in pathology). **a:** eligibility criteria for conversion therapy using immune checkpoint inhibitors (ICI) combined with antiangiogenic targeted drugs for advanced HCC. **b:** every 3 cycles of the immuno-targeted conversion therapy should be followed by an evaluation of the treatment response. The evaluation interval can be adjusted based on disease progression or the patient's condition. **c:** successful conversion criteria as downstaging and/or achieving technical resectability after conversion therapy. **d:** liver transplantation should be considered for patients with decompensated liver function. **e:** during initial and subsequent efficacy evaluations (based on modified RECIST criteria), if tumor shrinkage is $< 30\%$ or tumor growth is $< 20\%$, local therapies may be added under the guidance of a multidisciplinary team (MDT).

following multidisciplinary team collaboration (131). Multidisciplinary team collaboration should occur throughout the entire process of conversion therapy, including formulation of a treatment plan, evaluation of surgical indications and the timing of surgery, management of adverse events, monitoring of treatment response, and long-term follow-up (Figure 1).

Consensus 18

Decisions on conversion therapy regimens, evaluation of response, the timing of surgery, and postoperative adjuvant therapy for advanced HCC should follow a standardized, individualized, and comprehensive management approach based on multidisciplinary team collaboration (Evidence Level 3, Recommendation B).

4. Prospects for the future

China has a large population of patients with advanced HCC who have complex disease, limited effective treatment options, and a poor prognosis. Improving therapeutic outcomes for advanced HCC remains a critical challenge and aligns with the focus of the Healthy China 2030 plan to reduce mortality from major diseases. The aggressive biological behavior of advanced HCC limits the efficacy of standalone treatments - be they local therapy, systemic therapy, or surgical intervention - hampering the achievement of a radical cure or the provision of a long-term survival benefit. The emergence of conversion therapy offers a new avenue for treatment of advanced HCC. Over the past few years in particular, ICIs combined with AATDs have displayed encouraging results. Looking ahead, capitalizing on the collective decision-making of MDTs and combining ICIs and AATDs with other appropriate local therapies to devise a comprehensive treatment strategy should significantly improve the feasibility and increase the success rate of conversion therapy. This, in turn, could allow more patients with advanced HCC to undergo radical resection and provide them with long-term survival benefits.

Acknowledgements

The authors would like to express their gratitude to Xiaochen Xu, Junfeng Li, Xuerui Li, Tianyu Jiao, Fangzhou Wang, Zikun Ran for their assistance with the literature search and data compilation. Haowen Tang, Wenwen Zhang, Junning Cao, Yinbiao Cao, Xinyu Bi and Haitao Zhao contributed equally to this work. Haowen Tang, Wenwen Zhang, Junning Cao, Yinbiao Cao, Xinyu Bi, Haitao Zhao, and Shichun Lu contributed to draft writing. Shichun Lu and Jianqiang Cai contributed to the conception and design. Other experts participated in consensus discussion and suggestions.

Funding: None.

Conflict of Interest: The authors have no conflicts of interest to disclose.

References

- Zheng R, Chen R, Han B, Wang S, Li L, Sun K, Zeng H, Wei W, He J. Cancer incidence and mortality in China, 2022. *Chin J Oncol.* 2024; 46:221-231. (in Chinese)
- Sung H, Ferlay J, Siegel RL, Laversanne M, Soerjomataram I, Jemal A, Bray F. Global cancer statistics 2020: GLOBOCAN estimates of incidence and mortality worldwide for 36 cancers in 185 countries. *CA Cancer J Clin.* 2021; 71:209-249.
- National Health Commission of the People's Republic of China. Standard for diagnosis and treatment of primary liver cancer (2024 edition). *Chin J Hepatol.* 2024; 32:581-630. (in Chinese)
- Xiang X, Zhong JH, Wang YY, You XM, Ma L, Xiang BD, Li LQ. Distribution of tumor stage and initial treatment modality in patients with primary hepatocellular carcinoma. *Clin Translat Oncol.* 2017; 19:891-897.
- Liver EAftSot: EASL Clinical Practice Guidelines: Management of hepatocellular carcinoma. *J Hepatol.* 2018; 69:182-236.
- Reig M, Forner A, Rimola J, Ferrer-fàbrega J, Burrel M, Garcia-criado Á, Kelley RK, Galle PR, Mazzaferro V, Salem R, Sangro B, Singal AG, Vogel A, Fuster J, Ayuso C. BCLC strategy for prognosis prediction and treatment recommendation: The 2022 update. *J Hepatol.* 2022;76:681-693.
- National Health Commission of the People's Republic of China. Standard for diagnosis and treatment of primary liver cancer (2022 edition). *J Clin Hepatol.* 2022; 38:288-303. (in Chinese)
- Network NCC: NCCN Clinical Practice Guidelines in Oncology: Hepatocellular Carcinoma (Version 1.2024).
- Tang H, Cao Y, Jian Y, Li X, Li J, Zhang W, Wan T, Liu Z, Tang W, Lu S. Conversion therapy with an immune checkpoint inhibitor and an antiangiogenic drug for advanced hepatocellular carcinoma: A review. *Biosci Trends.* 2022; 16:130-141.
- Professional Committee for Prevention and Control of Hepatobiliary and Pancreatic Diseases of Chinese Preventive Medicine Association, Chinese Society of Liver Cancer, Liver Study Group of Surgery Committee of Beijing Medical Association, Editorial Board of the *Chin J Hepatobiliary Surg*, Lu S, Cai J. Chinese expert consensus on conversion therapy with immune checkpoint inhibitors combined with antiangiogenic targeted drugs for advanced hepatocellular carcinoma (2021 edition). *Chin J Hepatobiliary Surg.* 2021; 27:241-251. (in Chinese)
- Alliance of Liver Cancer Conversion Therapy, Committee of Liver Cancer of the Chinese Anti-Cancer Association, Fan J. Chinese expert consensus on conversion therapy in hepatocellular carcinoma (2021 edition). *Chin J Dig Surg.* 2021; 20:600-616. (in Chinese)
- Alliance of Liver Cancer Conversion Therapy, Committee of Liver Cancer, China Anti-Cancer Association; Fan J, Bai X. Chinese expert consensus on conversion and perioperative therapy of primary liver cancer (2024 edition). *Chin J Dig Surg.* 2024; 23:492-513. (in Chinese)
- Liver Oncology Branch, China Association for the

- Promotion of International Exchange in Healthcare; Immunology Branch, China Association for the Promotion of International Exchange in Healthcare; Cooperative Group for the Chinese Expert Consensus on Targeted Immunotherapy Combined with Local Therapy for Advanced Hepatocellular Cancer. Chinese expert consensus on targeted immunotherapy combined with local therapy for advanced hepatocellular cancer. *J Clin Hepatol.* 2023; 39:2782-2792. (in Chinese)
14. Que J, Lin CH, Lin LC, Ho CH. Challenges of BCLC stage C hepatocellular carcinoma: Results of a single-institutional experience on stereotactic body radiation therapy. *Medicine.* vol. 99; 2020:e21561.
 15. Su TS, Li LQ, Meng WW, Wang YD, Chen YT, Li JX, Du YQ, Qu S, Zhao C, Huang DJ, Liang SX, Li LQ. Long-term survival analysis of transarterial chemoembolization plus radiotherapy vs. radiotherapy for hepatocellular carcinoma with macroscopic vascular invasion. *Frontiers Oncol.* 2020; 10:1205.
 16. Clinical Guidelines Committee of the Chinese College of Interventionalists. Chinese clinical practice guidelines for transarterial chemoembolization of hepatocellular carcinoma (2023 edition). *Natl Med J China.* 2023; 103:2674-2694. (in Chinese)
 17. Hyun MH, Lee Y-S, Kim JH, Lee CU, Jung YK, Seo YS, Yim HJ, Yeon JE, Byun KS: Hepatic resection compared to chemoembolization in intermediate- to advanced-stage hepatocellular carcinoma: A meta-analysis of high-quality studies. *Hepatol.* 2018; 68:977-993.
 18. Le Y, Shen JX, Zhang YF, He MK, Kan A, Chen HL, Yu ZS, Li QJ, Shi M. Transarterial chemoembolization related to good survival for selected patients with advanced hepatocellular carcinoma. *J Cancer.* 2019; 10:665-671.
 19. Choi JW, Kim HC, Lee JH, Yu SJ, Kim YJ, Yoon -H, Jae HJ, Hur S, Lee M, Chung JW. Transarterial chemoembolization of hepatocellular carcinoma with segmental portal vein tumour thrombus. *Euro Radiol.* 2017; 27:1448-1458.
 20. Gorodetski B, Chapiro J, Scherthaner R, Duran R, Lin M, Lee H, Lenis D, Stuart EA, Nonyane BAS, Pekurovsky V, Tamrazi A, Gebauer B, Schlachter T, Pawlik TM, Geschwind JF. Advanced-stage hepatocellular carcinoma with portal vein thrombosis: conventional versus drug-eluting beads transcatheter arterial chemoembolization. *Euro Radiol.* 2017; 27:526-535.
 21. Lee SW, Lee TY, Peng YC, Yang SS, Yeh HZ, Chang CS. The therapeutic benefits of combined sorafenib and transarterial chemoembolization for advanced hepatocellular carcinoma. *J Digestive Diseases.* 2020; 21:287-292.
 22. Fan W, Yuan G, Fan H, Li F, Wu Y, Zhao Y, Yao W, Wang Y, Xue M, Yang J, Li J. Apatinib combined with transarterial chemoembolization in patients with hepatocellular carcinoma and portal vein tumor thrombus: A multicenter retrospective study. *Clin Therapeut.* 2019; 41:1463-1476.
 23. Chinese Society of Liver Cancer, China Anti-Cancer Association. Chinese expert consensus on hepatic arterial infusion chemotherapy for hepatocellular carcinoma (2021 edition). *Chin J Dig Surg.* 2021; 20:754-759. (in Chinese)
 24. He MK, Le Y, Li QJ, Yu ZS, Li SH, Wei W, Guo RP, Shi M. Hepatic artery infusion chemotherapy using mFOLFOX versus transarterial chemoembolization for massive unresectable hepatocellular carcinoma: A prospective non-randomized study. *Chin J Cancer.* 2017; 36:1-8.
 25. Li QJ, He MK, Chen HW, Fang WQ, Zhou YM, Xu L, Wei W, Zhang YJ, Guo Y, Guo RP, Chen MS, Md MS. Hepatic arterial infusion of oxaliplatin, fluorouracil, and leucovorin versus transarterial chemoembolization for large hepatocellular carcinoma: A randomized phase iii trial. *J Clin Oncol.* 2022; 40:150-160.
 26. Huo YR, Eslick GD. Transcatheter arterial chemoembolization plus radiotherapy compared with chemoembolization alone for hepatocellular carcinoma: A systematic review and meta-analysis. *JAMA Oncol.* 2015; 1:756-765.
 27. Yoon SM, Ryoo BY, Lee SJ, Kim JH, Shin JH, An JH, Lee HC, Lim YS. Efficacy and safety of transarterial chemoembolization plus external beam radiotherapy vs sorafenib in hepatocellular carcinoma with macroscopic vascular invasion: A randomized clinical trial. *JAMA Oncol.* 2018; 4:661-669.
 28. Liu Y, Li Y, Gao F, Zhang Q, Yang X, Zhu B, Niu S, Huang Y, Hu Y, Li W, Wang X. Comparison of transcatheter arterial chemoembolization-radiofrequency ablation and transcatheter arterial chemoembolization alone for advanced hepatocellular carcinoma with macrovascular invasion using propensity score analysis: A retrospective cohort study. *J Oncol.* 2020; 2020:1341863
 29. Si ZM, Wang GZ, Qian S, Qu XD, Yan ZP, Liu R, Wang JH. Combination therapies in the management of large (≥ 5 cm) hepatocellular carcinoma: Microwave ablation immediately followed by transarterial chemoembolization. *J Vasc Interv Radiol.* 2016; 27:1577-1583.
 30. Li B, Qiu J, Zheng Y, Shi Y, Zou R, He W, Yuan Y, Zhang Y, Wang C, Qiu Z, Li K, Zhong C, Yuan Y. Conversion to resectability using transarterial chemoembolization combined with hepatic arterial infusion chemotherapy for initially unresectable hepatocellular carcinoma. *Annals Surg.* 2021; 2:e057.
 31. Finn RS, Qin S, Ikeda M. *et al.* Atezolizumab plus bevacizumab in unresectable hepatocellular carcinoma. *NEJM.* 2020; 382:1894-1905.
 32. Zhu AX, Finn RS, Edeline J. *et al.* Pembrolizumab in patients with advanced hepatocellular carcinoma previously treated with sorafenib (KEYNOTE-224): A non-randomised, open-label phase 2 trial. *Lancet Oncol.* 2018; 19:940-952.
 33. Finn RS, Ikeda M, Zhu AX. *et al.* Phase Ib study of lenvatinib plus pembrolizumab in patients with unresectable hepatocellular carcinoma. *J Clin Oncol.* 2020; 38:2960-2970.
 34. Llovet JM, Ricci S, Mazzaferro V. *et al.* Sorafenib in advanced hepatocellular carcinoma. *N Engl J Med.* 2008; 359:378-390
 35. Ren Z, Xu J, Bai Y. *et al.* Sintilimab plus a bevacizumab biosimilar (IBI305) versus sorafenib in unresectable hepatocellular carcinoma (ORIENT-32): A randomised, open-label, phase 2-3 study. *Lancet Oncol.* 2021; 22:977-990.
 36. Llovet JM, Kudo M, Merle P. *et al.* Lenvatinib plus pembrolizumab versus lenvatinib plus placebo for advanced hepatocellular carcinoma (LEAP-002): A randomised, double-blind, phase 3 trial. *Lancet Oncol.* 2023; 24:1399-1410.
 37. Qin S, Chan SL, Gu S. *et al.* Camrelizumab plus rivoceranib versus sorafenib as first-line therapy for unresectable hepatocellular carcinoma (CARES-310): A randomised, open-label, international phase 3 study. *Lancet.* 2023; 402:1133-1146.
 38. Qin S, Ren Z, Feng YH, Yau T, Wang B, Zhao H, Bai Y,

- Gu S, Li L, Hernandez S, Xu DZ, Mulla S, Wang Y, Shao H, Cheng AL. Atezolizumab plus bevacizumab versus sorafenib in the Chinese subpopulation with unresectable hepatocellular carcinoma: Phase 3 randomized, open-label IMbrave150 study. *Liver Cancer*. 2021; 10:296-308.
39. Galle PR, Decaens T, Kudo M. *et al.* Nivolumab (NIVO) plus ipilimumab (IPI) vs lenvatinib (LEN) or sorafenib (SOR) as first-line treatment for unresectable hepatocellular carcinoma (uHCC): First results from CheckMate 9DW. *J Clin Oncol*. 2024; 42(17 suppl):LBA4008-LBA4008.
 40. Abou-Alfa GK, Lau G, Kudo M. *et al.* Tremelimumab plus durvalumab in unresectable hepatocellular carcinoma. *NEJM Evid*. 2022; 1:EVIDoa2100070.
 41. Lencioni R, Kudo M, Erinjeri J. *et al.* EMERALD-1: A phase 3, randomized, placebo-controlled study of transarterial chemoembolization combined with durvalumab with or without bevacizumab in participants with unresectable hepatocellular carcinoma eligible for embolization. *J Clin Oncol*. 2024; 42:LBA432-LBA432.
 42. Peng Z, Fan W, Zhu B. *et al.* Lenvatinib combined with transarterial chemoembolization as first-line treatment for advanced hepatocellular carcinoma: A phase III, randomized clinical trial (LAUNCH). *J Clin Oncol*. 2023; 41:117-127.
 43. Zheng K, Zhu X, Fu S. *et al.* Sorafenib plus hepatic arterial infusion chemotherapy versus sorafenib for hepatocellular carcinoma with major portal vein tumor thrombosis: A randomized trial. *Radiol*. 2022; 303:455-464.
 44. Zhao M, Lyu N, Zhong S, Yi J, Chen S, Hu Y, Jiang X, Wang X, Chen Q. Safety and efficacy of durvalumab plus hepatic artery infusion chemotherapy in HCC with severe portal vein tumor thrombosis (Vp3/4) – The DurHope study. *Annals Oncol*. 2023; 34:S608.
 45. Zhu HD, Li HL, Huang MS. *et al.* Transarterial chemoembolization with PD-(L)1 inhibitors plus molecular targeted therapies for hepatocellular carcinoma (CHANCE001). *Signal Transduc Targeted Ther*. 2023; 8:58.
 46. Jin ZC, Chen JJ, Zhu XL *et al.* Immune checkpoint inhibitors and anti-vascular endothelial growth factor antibody/tyrosine kinase inhibitors with or without transarterial chemoembolization as first-line treatment for advanced hepatocellular carcinoma (CHANCE2201): A target trial emulat. In: *EClinicalMedicine*. 2024; 72:102622.
 47. Nong X, Zhang YM, Liang JC, Xie JL, Zhang ZM. Lenvatinib (LEN) combined with tislelizumab (TIS) plus transcatheter arterial chemoembolization (TACE) for unresectable hepatocellular carcinoma (uHCC): A single-arm, phase II clinical trial. *J Clin Oncol*. 2023; 41:4111.
 48. Qu S, Zhang X, Wu Y, Meng Y, Pan H, Fang Q, Hu L, Zhang J, Wang R, Wei L, Wu D. Efficacy and safety of TACE combined with lenvatinib plus pd-1 inhibitors compared with TACE alone for unresectable hepatocellular carcinoma patients: A prospective cohort study. *Frontiers Oncol*. 2022; 12:874473.
 49. Xu Y, Fu S, Mao Y, Huang S, Li D, Wu J. Hepatic arterial infusion chemotherapy (HAIC) combined with tislelizumab and lenvatinib for advanced hepatocellular carcinoma (aHCC) with Vp3-4 portal vein tumor thrombosis (PVTT): A single-arm, phase II study. *J Clin Oncol*. 2023; 41:e16145-e16145.
 50. Chen J, Zang M, Pang H, Li C, Zhao J, Guo Y, Hou J. Camrelizumab combined with lenvatinib and RALOX-HAIC for hepatocellular carcinoma (HCC) in BCLC stage B and C: A prospective, single-arm, phase II trial (Cal Era study). *J Clin Oncol*. 2023; 41:e16128-e16128.
 51. Giannini EG, Bucci L, Garuti F. *et al.* Patients with advanced hepatocellular carcinoma need a personalized management: A lesson from clinical practice. *Hepatol (Baltimore, Md)*. 2018; 67:1784-1796.
 52. Mei J, Li SH, Wang QX, Lu LH, Ling YH, Zou JW, Lin WP, Wen YH, Wei W, Guo RP. Resection vs. sorafenib for hepatocellular carcinoma with macroscopic vascular invasion: a real world, propensity score matched analytic study. *Frontiers Oncol*. 2020; 10:573.
 53. Costentin CE, Decaens T, Laurent A. *et al.* Sorafenib vs surgical resection for hepatocellular carcinoma with macrovascular invasion: A propensity score analysis. *Liver Internat*. 2017; 37:1869-1876.
 54. Cao L, Chen J, Duan T, Wang M, Jiang H, Wei Y, Xia C, Zhou X, Yan X, Song B. Diffusion kurtosis imaging (DKI) of hepatocellular carcinoma: Correlation with microvascular invasion and histologic grade. *Quantitat Imaging Med Surg*. 2019; 9:590-602.
 55. Koh YX, Tan HL, Lye WK, Kam JH, Chiow AKH, Tan SS, Choo SP, Chung AYP, Goh BKP: Systematic review of the outcomes of surgical resection for intermediate and advanced Barcelona Clinic Liver Cancer stage hepatocellular carcinoma: A critical appraisal of the evidence. *World J Hepatol*. 2018; 10:433-447.
 56. Komatsu S, Kido M, Tanaka M, Kuramitsu K, Tsugawa D, Awazu M, Gon H, Toyama H, Ueno K, Fukumoto T. Clinical relevance of reductive hepatectomy for barcelona clinic liver cancer stages b and c advanced hepatocellular carcinoma: a single-center experience of 102 patients. *World J Surg*. 2019; 43:2571-2578.
 57. Xia Y, Zhang F, Li X, *et al.* Surgical treatment of primary liver cancer: A report of 10,966 cases. *Chin J Surg*. 2021; 59:6-17. (in Chinese)
 58. Zhang W, Liu C, Tan Y, Jiang L, Yan L, Yang J, Wen T. Role of liver resection in treating intermediate and advanced stage adolescent and young adult hepatocellular carcinoma patients: A propensity-matching cohort study. *Internat J Surg (London, England)*. 2018; 54:259-264.
 59. Liu PH, Hsia CY, Lee YH, Hsu CY, Huang YH, Su CW, Lee RC, Lin HC, Huo TI. Surgical resection versus transarterial chemoembolization for BCLC stage C hepatocellular carcinoma. *J Surg Oncol*. 2015; 111:404-409.
 60. Zhu XD, Huang C, Shen YH, Xu B, Ge NL, Ji Y, Qu XD, Chen L, Chen Y, Li ML, Zhu JJ, Tang ZY, Zhou J, Fan J, Sun HC. Hepatectomy after conversion therapy using tyrosine kinase inhibitors plus anti-PD-1 antibody therapy for patients with unresectable hepatocellular carcinoma. *Ann Surg Oncol*. 2023; 30:2782-2790.
 61. Zhang W, Tong S, Hu B, *et al.* Lenvatinib plus anti-PD-1 antibodies as conversion therapy for patients with unresectable intermediate-advanced hepatocellular carcinoma: A single-arm, phase II trial. *J Immunother Cancer*. 2023; 11:e007366.
 62. Li X, Li J, Zhang W, Wang Z, Hu B, Tang H, Liu B, Wan T, Liu Z, Wang Z, Lu S. Long-term efficacy of sequential surgery after immune combined with targeted therapy for initially unresectable hepatocellular carcinoma. *Chin J Hepatobiliary Surg*. 2024; 30:9-14. (in Chinese)
 63. Lei J, Wang W, Yan L. Downstaging advanced hepatocellular carcinoma to the Milan criteria may provide

- a comparable outcome to conventional Milan criteria. *J Gastrointest Surg.* 2013; 17:1440-1446.
64. Chapman WC, Garcia-Aroz S, Vachharajani N, Fowler K, Saad N, Lin Y, Wellen J, Tan B, Khan AS, Doyle MBM. Liver transplantation for advanced hepatocellular carcinoma after downstaging without up-front stage restrictions. *J Amer Coll Surgeons.* 2017; 224:610-621.
 65. Yau T, Park JW, Finn RS *et al.* Nivolumab versus sorafenib in advanced hepatocellular carcinoma (CheckMate 459): A randomised, multicentre, open-label, phase 3 trial. *Lancet Oncol.* 2022; 23:77-90.
 66. Qin S, Kudo M, Meyer T. *et al.* Tislelizumab vs sorafenib as first-line treatment for unresectable hepatocellular carcinoma: A phase 3 randomized clinical trial. *JAMA Oncol.* 2023; 9:1651-1659.
 67. Kudo M, Finn RS, Qin S. *et al.* Lenvatinib versus sorafenib in first-line treatment of patients with unresectable hepatocellular carcinoma: A randomised phase 3 non-inferiority trial. *Lancet (London, England).* 2018; 391:1163-1173.
 68. Cheng AL, Kang YK, Chen Z. *et al.* Efficacy and safety of sorafenib in patients in the Asia-Pacific region with advanced hepatocellular carcinoma: A phase III randomised, double-blind, placebo-controlled trial. *Lancet Oncol.* 2009; 10:25-34.
 69. Qin S, Bi F, Gu S. *et al.* Donafenib versus sorafenib in first-line treatment of unresectable or metastatic hepatocellular carcinoma: A randomized, open-label, parallel-controlled phase II-III trial. *J Clin Oncol.* 2021; 39:3002-3011.
 70. Li S, Zhang Z, Wang Z, Wang K, Sui M, Liu D, Liang KUO. Lenvatinib-based treatment regimens in conversion therapy of unresectable hepatocellular carcinoma: A systematic review and meta-analysis. *Oncol Lett.* 2024; 27:265
 71. Kaneko S, Tsuchiya K, Yasui Y. *et al.* Conversion surgery for hepatocellular carcinoma after tyrosine kinase inhibitor treatment. *JGH Open.* 2022; 6:301-308.
 72. Komatsu S, Yano Y, Mimura T. *et al.* Current status of conversion hepatectomy after sorafenib and lenvatinib treatment for unresectable hepatocellular carcinoma. *Anticancer Res.* 2024; 44:3097-3103.
 73. Song T, Lang M, Ren S, Gan L, Lu W. The past, present and future of conversion therapy for liver cancer. *Am J Cancer Res.* 2021; 11:4711-4724.
 74. Li W, Pei Y, Wang Z, Liu J. Efficacy of transarterial chemoembolization monotherapy or combination conversion therapy in unresectable hepatocellular carcinoma: A systematic review and meta-analysis. *Front Oncol.* 2022; 12:930868.
 75. Li W, Zheng Z, Wang J, Wu T, Wang J, Pan Y, Chen J, Hu D, Xu L, Zhang Y, Chen M, Zhou Z. Efficacy and safety of conversion surgery for advanced hepatocellular carcinoma after hepatic arterial infusion chemotherapy. *J Hepatocell Carc.* 2024; 11:463-475.
 76. Lee HS, Choi GH, Choi JS, Kim KS, Han KH, Seong J, Ahn SH, Kim DY, Park JY, Kim SU, Kim BK. Surgical resection after down-staging of locally advanced hepatocellular carcinoma by localized concurrent chemoradiotherapy. *Ann Surg Oncol.* 2014; 21:3646-3653.
 77. Chong JU, Choi GH, Han DH, Kim KS, Seong J, Han K-H, Choi JS. Downstaging with localized concurrent chemoradiotherapy can identify optimal surgical candidates in hepatocellular carcinoma with portal vein tumor thrombus. *Ann Surg Oncol.* 2018; 25:3308-3315.
 78. Zhu XD, Huang C, Shen YH, Ji Y, Ge NL, Qu XD, Chen L, Shi WK, Li ML, Zhu JJ, Tan CJ, Tang ZY, Zhou J, Fan J, Sun HC: Downstaging and resection of initially unresectable hepatocellular carcinoma with tyrosine kinase inhibitor and anti-PD-1 antibody combinations. *Liver Cancer.* 2021; 10:320-329.
 79. Wang L, Wang H, Cui Y, Jin K, Liu W, Wang K, Xing B. Sintilimab plus lenvatinib as conversion therapy in patients with unresectable locally intermediate to advanced hepatocellular carcinoma: A single-arm, single-center, open-label, phase 2 study. *J Clin Oncol.* 2022; 40:449.
 80. Sun H, Zhu X, Gao Q. *et al.* Sintilimab combined with bevacizumab biosimilar as a conversion therapy in potentially resectable intermediate stage hepatocellular carcinoma (HCC): A phase II trial. *Ann Oncol.* 2022; 33:S867-S868.
 81. Yi Y, Sun BY, Weng JL, Zhou C, Zhou CH, Cai MH, Zhang JY, Gao H, Sun J, Zhou J, Fan J, Ren N, Qiu SJ. Lenvatinib plus anti-PD-1 therapy represents a feasible conversion resection strategy for patients with initially unresectable hepatocellular carcinoma: A retrospective study. *Frontiers Oncol.* 2022; 12:1046584.
 82. Cao Y, Tang H, Hu B. *et al.* Comparison of survival benefit between salvage surgery after conversion therapy versus surgery alone for hepatocellular carcinoma with portal vein tumor thrombosis: A propensity score analysis. *HPB.* 2023; 25:775-787.
 83. Li X, Zhang W, Hu B, Wan T, Liu Z, Tang H, Li J, Cao Y, Zhang Z, Wang Z, Lu S. Clinical efficacy of sequential surgery after immune and targeted therapy in downstaging initially unresectable hepatocellular carcinoma. *Chin J Hepatobiliary Surg.* 2023; 29:15-21. (in Chinese)
 84. Qin S, Chan LS, Gu S. *et al.* LBA35 Camrelizumab (C) plus rivoceranib (R) vs. sorafenib (S) as first-line therapy for unresectable hepatocellular carcinoma (uHCC): A randomized, phase III trial. *Ann Oncol.* 2022; 33:S1401-S1402.
 85. Song T, Lang M, Lu W, Zhang T, Li H, Wu Q, Cui Y, Zhang W, Li Q, Zang F, Xing W, Ren S, Gan L. Conversion of initially unresectable hepatocellular carcinoma (HCC) with triple-combination therapy (lenvatinib, anti-PD-1 antibodies, and transarterial therapy): A retrospective analysis. *J Clin Oncol.* 2022; 40:413.
 86. Llovet JM, De Baere T, Kulik L, Haber PK, Gretten TF, Meyer T, Lencioni R. Locoregional therapies in the era of molecular and immune treatments for hepatocellular carcinoma. *Nat Rev Gastroenterol Hepatol* 2021; 18:293-313.
 87. Brandi N, Renzulli M. The Synergistic effect of interventional locoregional treatments and immunotherapy for the treatment of hepatocellular carcinoma. *Int J Mol Sci.* 2023; 24:8598.
 88. Hong Z, Lei G, Song B, Hu X, Wang S. Donafenib, anti-PD-1 antibodies, plus hepatic arterial infusion chemotherapy (HAIC) as conversion therapy in patients with initially unresectable hepatocellular carcinoma (HCC): A prospective, single-arm, phase 2 study. *J Clin Oncol.* 2023; 41:e16140-e16140.
 89. Zhang Z, Yan M, Chen Y, Wu X, Yang L, Yin Z, Lu H, Zeng Y, Zhang H, Huang J, Chen J, Wang L, Chen Z. Transarterial chemoembolization combined with lenvatinib and camrelizumab for unresectable hepatocellular

- carcinoma: A prospective, single-arm, multicenter study. *J Clin Oncol.* 2023; 41(16_suppl):4072-4072.
90. Dong W, Zhang S, Huo Z, Lu J, Liu H, Wang P, Zhang Y. Lenvatinib in combination with PD-1 inhibitor and hepatic arterial infusion chemotherapy (HAIC) for patients with potentially resectable hepatocellular carcinoma: A retrospective analysis. *J Clin Oncol.* 2023; 41:e16160-e16160.
 91. Xue J, Ni H, Wang F, Xu K, Niu M: Advances in locoregional therapy for hepatocellular carcinoma combined with immunotherapy and targeted therapy. *J Interv Med.* 2021; 4:105-113.
 92. Li B, Wang C, He W, Qiu J, Zheng Y, Zou R, Lin Z, Shi Y, Yuan Y, Zhang R, Zhang C, Chen M, Lau WY, Yuan Y. Watch-and-wait strategy vs. resection in patients with radiologic complete response after conversion therapy for initially unresectable hepatocellular carcinoma: A propensity score-matching comparative study. *Internat J Surg.* 2024; 110:2545-2555.
 93. Wu JY, Wu JY, Fu YK, Ou XY, Li SQ, Zhang ZB, Zhou JY, Li B, Wang SJ, Chen YF, Yan ML. Outcomes of salvage surgery versus non-salvage surgery for initially unresectable hepatocellular carcinoma after conversion therapy with transcatheter arterial chemoembolization combined with lenvatinib plus anti-PD-1 antibody: A multicenter retrospective study. *Ann Surg Oncol.* 2024; 31:3073-3083.
 94. Lau WY, Lai ECH. Salvage surgery following downstaging of unresectable hepatocellular carcinoma – A strategy to increase resectability. *Ann Surg Oncol.* 2007; 14:3301-3309.
 95. Shi XJ, Jin X, Wang MQ, Wei LX, Ye HY, Liang YR, Luo Y, Dong JH. Effect of resection following downstaging of unresectable hepatocellular carcinoma by transcatheter arterial chemoembolization. *Chin Med J.* 2012; 125:197-202.
 96. Liu J, Zhu X, Pan Y. *et al.* Prognoses of patients treated with surgical therapy versus continuation of local-plus-systemic therapy following successful down-staging of intermediate-advanced hepatocellular carcinoma: A multicenter real-world study. *Oncologist.* 2024; 29:e487-e497.
 97. Zhang X, Zhu X, Zhong J. *et al.* Surgical treatment improves overall survival of hepatocellular carcinoma with extrahepatic metastases after conversion therapy: A multicenter retrospective study. *Scientific Reports.* 2024; 14:9745.
 98. Tran NH, Muñoz S, Thompson S, Hallemeier CL, Bruix J. Hepatocellular carcinoma downstaging for liver transplantation in the era of systemic combined therapy with anti-VEGF/TKI and immunotherapy. *Hepatology.* 2022; 76:1203-1218.
 99. Yu H, Bai Y, Xie X, Feng Y, Yang Y, Zhu Q. RECIST 1.1 versus mRECIST for assessment of tumour response to molecular targeted therapies and disease outcomes in patients with hepatocellular carcinoma: A systematic review and meta-analysis. *BMJ Open.* 2022; 12:e052294.
 100. Jung J, Joo JH, Kim SY, Kim JH, Choi J, Lee D, Shim JH, Kim KM, Lim YS, Lee HC, Park JH, Yoon SM. Radiologic response as a prognostic factor in advanced hepatocellular carcinoma with macroscopic vascular invasion after transarterial chemoembolization and radiotherapy. *Liver Cancer.* 2022; 11:152-161.
 101. Arizumi T, Ueshima K, Chishina H, Kono M, Takita M, Kitai S, Inoue T, Yada N, Hagiwara S, Minami Y, Sakurai T, Nishida N, Kudo M. Decreased blood flow after sorafenib administration is an imaging biomarker to predict overall survival in patients with advanced hepatocellular carcinoma. *Digestive Diseases (Basel, Switzerland).* 2014; 32:733-739.
 102. Bae JS, Lee JM, Yoon JH, Jang S, Chung JW, Lee KB, Yi NJ, Lee JH. How to best detect portal vein tumor thrombosis in patients with hepatocellular carcinoma meeting the Milan criteria: Gadoxetic acid-enhanced MRI versus contrast-enhanced CT. *Liver Cancer.* 2020; 9:293-307.
 103. Chernyak V, Fowler KJ, Kamaya A, Kielar AZ, Elsayes KM, Bashir MR, Kono Y, Do RK, Mitchell DG, Singal AG, Tang A, Sirlin CB. Liver Imaging Reporting and Data System (LI-RADS) Version 2018: Imaging of hepatocellular carcinoma in at-risk patients. *Radiol.* 2018; 289:816-830.
 104. Catalano OA, Choy G, Zhu A, Hahn PF, Sahani DV. Differentiation of malignant thrombus from bland thrombus of the portal vein in patients with hepatocellular carcinoma: Application of diffusion-weighted MR imaging. *Radiol.* 2010; 254:154-162.
 105. Granata V, Fusco R, Amato DM, Albino V, Patrone R, Izzo F, Petrillo A: Beyond the vascular profile: conventional DWI, IVIM and kurtosis in the assessment of hepatocellular carcinoma. *Euro Rev Med Pharmacol Sci.* 2020; 24:7284-7293.
 106. Lu TL, Becce F, Bize P, Denys A, Meuli R, Schmidt S. Assessment of liver tumor response by high-field (3 T) MRI after radiofrequency ablation: short- and mid-term evolution of diffusion parameters within the ablation zone. *Euro J Radiol.* 2012; 81:e944-950.
 107. Sun DW, An L, Wei F, Mu L, Shi XJ, Wang CL, Zhao ZW, Li TF, Lv GY. Prognostic significance of parameters from pretreatment ¹⁸F-FDG PET in hepatocellular carcinoma: A meta-analysis. *Abdominal Radiol (New York).* 2016; 41:33-41.
 108. Wang G, Zhang W, Chen J, Luan X, Wang Z, Wang Y, Xu X, Yao S, Guan Z, Tian J, Lu S, Xu B, Ma G. Pretreatment metabolic parameters measured by ¹⁸F-fdg pet to predict the pathological treatment response of HCC patients treated with pd-1 inhibitors and lenvatinib as a conversion therapy in BCLC stage C. *Frontiers Oncol.* 2022; 12:884372.
 109. Wang G, Zhang W, Luan X, Wang Z, Liu J, Xu X, Zhang J, Xu B, Lu S, Wang R, Ma G: The role of ¹⁸F-FDG PET in predicting the pathological response and prognosis to unresectable HCC patients treated with lenvatinib and PD-1 inhibitors as a conversion therapy. *Frontiers Immunol.* 2023; 14:1151967.
 110. Shao YY, Liu TH, Hsu C, Lu LC, Shen YC, Lin ZZ, Cheng AL, Hsu CH. Early alpha-fetoprotein response associated with treatment efficacy of immune checkpoint inhibitors for advanced hepatocellular carcinoma. *Liver Internl.* 2019; 39:2184-2189.
 111. Cao Y, Li J, Tang H, Wan T, Liu Z, Hu B, Jiang H, Lu S. Serum alpha-fetoprotein in predicting survival of patients with BCLC C hepatocellular carcinoma treated by salvage surgery after downstaging therapy. *Chin J Hepatobiliary Surg.* 2023; 29:22-27. (in Chinese)
 112. Huang C, Zhu XD, Shen YH. *et al.* Radiographic and α -fetoprotein response predict pathologic complete response to immunotherapy plus a TKI in hepatocellular carcinoma: A multicenter study. *BMC Cancer.* 2023; 23:416.

113. Sun X, Mei J, Lin W, Yang Z, Peng W, Chen J, Zhang Y, Xu L, Chen M. Reductions in AFP and PIVKA-II can predict the efficiency of anti-PD-1 immunotherapy in HCC patients. *BMC Cancer*. 2021; 21:775.
114. Dharmapuri S, Özbek U, Lin JY, Sung M, Schwartz M, Branch AD, Ang C. Predictive value of neutrophil to lymphocyte ratio and platelet to lymphocyte ratio in advanced hepatocellular carcinoma patients treated with anti-PD-1 therapy. *Cancer Med*. 2020; 9:4962-4970.
115. Kubota K, Makuuchi M, Kusaka K, Kobayashi T, Miki K, Hasegawa K, Harihara Y, Takayama T. Measurement of liver volume and hepatic functional reserve as a guide to decision-making in resectional surgery for hepatic tumors. *Hepatol*. 1997; 26:1176-1181.
116. Vauthey JN, Chaoui A, Do KA, Bilimoria MM, Fenstermacher MJ, Charnsangavej C, Hicks M, Alsfasser G, Lauwers G, Hawkins IF, Caridi J. Standardized measurement of the future liver remnant prior to extended liver resection: Methodology and clinical associations. *Surgery*. 2000; 127:512-519.
117. Luo L, He Y, Zhu G, Xiao Y, Song S, Ge X, Wang T, Xie J, Deng W, Hu Z, Shan R. Hepatectomy after conversion therapy for initially unresectable HCC: What is the difference? *J Hepatocell Carc*. 2022; 9:1353-1368.
118. Jiao T, Tang H, Zhang W, Hu B, Wan T, Cao Y, Zhang Z, Wang Y, Cao J, Cui M, Lu S. Long-term survival and portal vein patency with novel PVTT surgery approach in advanced HCC patients with Vp3/4 PVTT following combination therapy of TKIs and PD-1 inhibitors. *BMC Surg*. 2023; 23:384.
119. Li J, Yuan J, Zhang W, Wang Z, Li X, Liu Z, Wan T, Hu B, Cao J, Lu S. Value of the ratio of viable tumor cells in the prognostic evaluation for patients with unresectable hepatocellular carcinoma undergoing sequential surgery after conversional therapy. *Chin J Hepatobiliary Surg*. 2024; 30:241-247. (in Chinese)
120. Ohya Y, Hayashida S, Tsuji A, Kuramoto K, Shibata H, Setoyama H, Hayashi H, Kuriwaki K, Sasaki M, Iizaka M, Nakahara O, Inomata Y. Conversion hepatectomy for advanced hepatocellular carcinoma after right portal vein transection and lenvatinib therapy. *Surgical Case Reports*. 2020; 6:318.
121. Tomonari T, Sato Y, Tanaka H, Tanaka T, Taniguchi T, Sogabe M, Okamoto K, Miyamoto H, Muguruma N, Saito Y, Imura S, Bando Y, Shimada M, Takayama T. Conversion therapy for unresectable hepatocellular carcinoma after lenvatinib: Three case reports. *Medicine*. 2020; 99:e22782.
122. Chow P, Chen M, Cheng AL, *et al*. IMbrave050: Phase 3 study of adjuvant atezolizumab + bevacizumab versus active surveillance in patients with hepatocellular carcinoma (HCC) at high risk of disease recurrence following resection or ablation. *Cancer Res*. 2023; 83:CT003.
123. Wang K, Xiang YJ, Yu HM, *et al*. Adjuvant sintilimab in resected high-risk hepatocellular carcinoma: A randomized, controlled, phase 2 trial. *Nature Med*. 2024; 30:708-715.
124. Li L, Wu PS, Liang XM, Chen K, Zhang GL, Su QB, Huo RR, Xie RW, Huang S, Ma L, Zhong JH. Adjuvant immune checkpoint inhibitors associated with higher recurrence-free survival in postoperative hepatocellular carcinoma (PREVENT): A prospective, multicentric cohort study. *J Gastroenterol*. 2023; 58:1043-1054.
125. Chen W, Hu S, Liu Z, Sun Y, Wu J, Shen S, Peng Z. Adjuvant anti-PD-1 antibody for hepatocellular carcinoma with high recurrence risks after hepatectomy. *Hepatol Interntl*. 2023; 17:406-416.
126. Qin S, Chen M, Cheng AL *et al*. Atezolizumab plus bevacizumab versus active surveillance in patients with resected or ablated high-risk hepatocellular carcinoma (IMbrave050): A randomised, open-label, multicentre, phase 3 trial. *Lancet*. 2023; 402:1835-1847.
127. Ran Z, Tang H, Cao Y, Zhang W, Liu Z, Wan T, Li X, Li J, Jiao T, Lu S. A retrospective study of postoperative adjuvant therapy following immunotherapy combined with targeted therapy and sequential curative surgical procedures for initially unresectable hepatocellular carcinoma. *Chin J Surg*. 2024; 62:543-548. (in Chinese)
128. Lu S, Gu W. Essentials of precision medicine in practice of surgical oncology for hepatobiliary tumors. *Chin J Hepatobiliary Surg*. 2019; 25:1-4. (in Chinese)
129. Thompson JA, Schneider BJ, Brahmer J, *et al*. NCCN Guidelines Insights: Management of Immunotherapy-Related Toxicities, Version 2.2024: Featured Updates to the NCCN Guidelines. *J Natl Compr Canc Netw*. 2024; 22: 582-592.
130. Xin H, Xie Q. Management of adverse effects related to systemic anti-tumor therapies for advanced hepatocellular carcinoma. *J Clin Intern Med*. 2022; 39:806-810. (in Chinese)
131. The Chinese Chapter of the International Hepato-Pancreato-Biliary Association; Group of Liver Surgery, Surgical Society of Chinese Medical Association; Expert Committee on Liver Cancer, Chinese Society of Clinical Oncology; Chen X, Xia F. Chinese multidisciplinary expert consensus on combined immunotherapy for hepatocellular carcinoma (2023 version). *Chin J Hepatol*. 2023; 22:293-315. (in Chinese)
132. Shi G, Huang X, Ren Z. Chinese expert consensus on the management of immune-related adverse events of hepatocellular carcinoma treated with immune checkpoint inhibitors (2021 edition). *Chin J Dig Surg*. 2021; 20:1241-1258. (in Chinese)

Received November 29, 2024; Revised December 22, 2024; Accepted December 23, 2024.

§These authors contributed equally to this work.

*Address correspondence to:

Shichun Lu, Faculty of Hepato-Pancreato-Biliary Surgery, the First Medical Center of the Chinese PLA General Hospital, Institute of Hepatobiliary Surgery of the Chinese PLA, No. 28 Fuxing Road, Beijing 100853, China.
E-mail: lusc_plagh@163.com

Released online in J-STAGE as advance publication December 25, 2024.